PREFERRED PRACTICE PATTERN®

Diabetic Retinopathy

AMERICAN ACADEMY OF OPHTHALMOLOGY
The Eye M.D. Association

Prepared by the American Academy of Ophthalmology Retina/Vitreous Panel

Retina/Vitreous Panel Members
Emily Y. Chew, MD, Chair, Macula Society and Retina Society Representative
William E. Benson, MD
Barbara A. Blodi, MD
H. Culver Boldt, MD
Timothy G. Murray, MD, Consultant and American Society of Retina Specialists Representative
Timothy W. Olsen, MD
Carl D. Regillo, MD, FACS
Ingrid U. Scott, MD, MPH
Leslie Hyman, PhD, Methodologist

Preferred Practice Patterns Committee Members
Sid Mandelbaum, MD, Chair
Emily Y. Chew, MD
Linda M. Christmann, MD
Douglas E. Gaasterland, MD
Samuel Masket, MD
Stephen D. McLeod, MD
Christopher J. Rapuano, MD
Donald S. Fong, MD, MPH, Methodologist

Academy Staff
Flora C. Lum, MD
Nancy Collins, RN, MPH
Doris Mizuiri
Medical Editor: Susan Garratt
Design: Socorro Soberano
Reviewed by: Council
Approved by: Board of Trustees
September 27, 2008

2nd Printing: September 2010
3rd Printing: September 2011
4th Printing: October 2012

This document should be cited as:
American Academy of Ophthalmology Retina Panel. Preferred Practice Pattern® Guidelines. Diabetic Retinopathy. San Francisco, CA: American Academy of Ophthalmology; 2008 (4th printing 2012). Available at: www.aao.org/ppp.

As a service to its members and the public, the American Academy of Ophthalmology has developed a series of guidelines called Preferred Practice Patterns that **identify characteristics and components of quality eye care.** (See Appendix 1.)

The Preferred Practice Pattern® guidelines are based on the best available scientific data as interpreted by panels of knowledgeable health professionals. In some instances, such as when results of carefully conducted clinical trials are available, the data are particularly persuasive and provide clear guidance. In other instances, the panels have to rely on their collective judgment and evaluation of available evidence.

Preferred Practice Patterns provide guidance for the pattern of practice, not for the care of a particular individual. While they should generally meet the needs of most patients, they cannot possibly best meet the needs of all patients. Adherence to these Preferred Practice Patterns will not ensure a successful outcome in every situation. These practice patterns should not be deemed inclusive of all proper methods of care or exclusive of other methods of care reasonably directed at obtaining the best results. It may be necessary to approach different patients' needs in different ways. The physician must make the ultimate judgment about the propriety of the care of a particular patient in light of all of the circumstances presented by that patient. The American Academy of Ophthalmology is available to assist members in resolving ethical dilemmas that arise in the course of ophthalmic practice.

The Preferred Practice Pattern® guidelines are not medical standards to be adhered to in all individual situations. The Academy specifically disclaims any and all liability for injury or other damages of any kind, from negligence or otherwise, for any and all claims that may arise out of the use of any recommendations or other information contained herein.

References to certain drugs, instruments, and other products are made for illustrative purposes only and are not intended to constitute an endorsement of such. Such material may include information on applications that are not considered community standard, that reflect indications not included in approved FDA labeling, or that are approved for use only in restricted research settings. The FDA has stated that it is the responsibility of the physician to determine the FDA status of each drug or device he or she wishes to use, and to use them with appropriate patient consent in compliance with applicable law.

Innovation in medicine is essential to assure the future health of the American public, and the Academy encourages the development of new diagnostic and therapeutic methods that will improve eye care. It is essential to recognize that true medical excellence is achieved only when the patients' needs are the foremost consideration.

All PPPs are reviewed by their parent panel annually or earlier if developments warrant and updated accordingly. To ensure that all PPPs are current, each is valid for 5 years from the "approved by" date unless superseded by a revision. Preferred Practice Pattern guidelines are developed by the Academy's H. Dunbar Hoskins Jr., M.D. Center for Quality Eye Care without any external financial support. Authors and reviewers of PPPs are volunteers and do not receive any financial compensation for their contributions to the documents. The PPPs are externally reviewed by experts and stakeholders before publication.

FINANCIAL DISCLOSURES

These panel and committee members have disclosed the following financial relationships occurring from January 2007 to October 2008:

H. Culver Boldt, MD: Alcon Laboratories, Inc. – Consultant/Advisor

Donald S. Fong, MD, MPH: Merck – Consultant/Advisor

Douglas E. Gaasterland, MD: Inspire Pharmaceuticals – Consultant/Advisor; IRIDEX – Consultant/Advisor, Equity owner, Patents/Royalty

Samuel Masket, MD: Alcon Laboratories, Inc. – Consultant/Advisor, Lecture fees, Grant support; Allergan, Inc. – Lecture fees; Bausch & Lomb, Inc. – Lecture fees; Omeros Pharmaceuticals, Inc. – Consultant/Advisor; Othera Pharmaceuticals, Inc. – Consultant/Advisor; PowerVision – Consultant/Advisor; Visiogen, Inc. – Consultant/Advisor

Stephen D. McLeod, MD: Alcon Laboratories, Inc. – Consultant/Advisor, Grant support; InSite Vision, Inc. – Consultant/Advisor, Visiogen, Inc. – Consultant/Advisor, Equity owner, Grant support

Timothy W. Olsen, MD: iScience – Grant support; Powerscope, Inc. – Grant support

Christopher J. Rapuano, MD: Alcon Laboratories, Inc. – Lecture fees; Allergan, Inc. – Consultant/Advisor, Lecture fees; Inspire Pharmaceuticals – Lecture fees; Ista Pharmaceuticals – Lecture fees; Rapid Pathogen Screening – Equity/owner; Ziemer Ophthalmic Systems AG – Consultant/Advisor

Carl D. Regillo, MD, FACS: Alcon Laboratories, Inc. – Consultant/Advisor; Eyetech, Inc. – Consultant/Advisor, Grant support; Genentech, Inc. – Consultant/Advisor, Grant support; Novartis – Consultant/Advisor, Grant support; QLT Phototherapeutics, Inc. – Consultant/Advisor, Grant support

Ingrid U. Scott, MD, MPH: Eyetech, Inc. – Consultant/Advisor, Lecture fees; Genentech, Inc. – Consultant/Advisor, Lecture fees; Pfizer Ophthalmics – Consultant/Advisor, Lecture fees

TABLE OF CONTENTS

INTRODUCTION 2
ORIENTATION 3
Entity 3
Disease Definition 3
Patient Population 3
Activity 3
Purpose 3
Goals 3
BACKGROUND 3
Epidemiology 3
Risk Factors 4
Natural History 4
PREVENTION AND EARLY DETECTION 6
CARE PROCESS 8
Patient Outcome Criteria 9
Diagnosis 9
- History 9
- Examination 9
- Examination Schedule 9
  - Type 1 (Diabetes Onset Usually Before Age 30 Years) 9
  - Type 2 (Diabetes Onset Usually at Age 30 Years or Older) 10
  - Diabetes Associated with Pregnancy 10
- Ancillary Tests 10
  - Color Fundus Photography 10
  - Optical Coherence Tomography 10
  - Fluorescein Angiography 10
  - Ultrasonography 11

Treatment 11
- Normal or Minimal NPDR 11
- Mild to Moderate NPDR Without Macular Edema 12
- Mild to Moderate NPDR with CSME 13
- Severe NPDR with Non-High-Risk PDR 14
- High-Risk PDR 15
- High-Risk PDR Not Amenable to Photocoagulation 15
- Other Treatments 16

Follow-up 16
- History 16
- Examination 16

Provider 16
Physician Quality Reporting System 17
Counseling/Referral 17
APPENDIX 1. QUALITY OF OPHTHALMIC CARE CORE CRITERIA 18
APPENDIX 2. SUMMARY OF MAJOR RECOMMENDATIONS FOR CARE 20
APPENDIX 3. TREATMENT TRIAL RESULTS 23
APPENDIX 4. GLYCEMIC CONTROL 25
APPENDIX 5. CLASSIFICATION OF DIABETIC RETINOPATHY IN THE EARLY TREATMENT OF DIABETIC RETINOPATHY STUDY 26
APPENDIX 6. COST-BENEFIT ANALYSES 27
GLOSSARY 28
RELATED ACADEMY MATERIALS 31
REFERENCES 32

INTRODUCTION

The Preferred Practice Pattern® (PPP) guidelines have been written on the basis of three principles.

- Each Preferred Practice Pattern should be clinically relevant and specific enough to provide useful information to practitioners.
- Each recommendation that is made should be given an explicit rating that shows its importance to the care process.
- Each recommendation should also be given an explicit rating that shows the strength of evidence that supports the recommendation and reflects the best evidence available.

In the process of revising this document, a detailed literature search of articles in the English language was conducted on the subject of diabetic retinopathy for the years 2002 to 2007. The results were reviewed by the Retina Panel and used to prepare the recommendations, which they rated in two ways. The panel first rated each recommendation according to its importance to the care process. This "importance to the care process" rating represents care that the panel thought would improve the quality of the patient's care in a meaningful way. The ratings of importance are divided into three levels.

- Level A, defined as most important
- Level B, defined as moderately important
- Level C, defined as relevant but not critical

The panel also rated each recommendation on the strength of evidence in the available literature to support the recommendation made. The "ratings of strength of evidence" also are divided into three levels.

- Level I includes evidence obtained from at least one properly conducted, well-designed, randomized controlled trial. It could include meta-analyses of randomized controlled trials.
- Level II includes evidence obtained from the following:
  - Well-designed controlled trials without randomization
  - Well-designed cohort or case-control analytic studies, preferably from more than one center
  - Multiple-time series with or without the intervention
- Level III includes evidence obtained from one of the following:
  - Descriptive studies
  - Case reports
  - Reports of expert committees/organizations (e.g., PPP panel consensus with external peer review)

The evidence cited is that which supports the value of the recommendation as something that should be performed to improve the quality of care. The panel believes that it is important to make available the strength of the evidence underlying the recommendation. In this way, readers can appreciate the degree of importance the committee attached to each recommendation and they can understand what type of evidence supports the recommendation.

The ratings of importance and the ratings of strength of evidence are given in bracketed superscripts after each recommendation. For instance, "[A:II]" indicates a recommendation with high importance to clinical care [A], supported by sufficiently rigorous published evidence, though not by a randomized controlled trial [II].

The sections entitled Orientation and Background do not include recommendations; rather they are designed to educate and provide summary background information and rationale for the recommendations that are presented in the Care Process section. A summary of the major recommendations for care is included in Appendix 2.

ORIENTATION

ENTITY

Diabetic retinopathy (ICD-9 #362.01 - 362.07)

DISEASE DEFINITION

Diabetic retinopathy is a disorder of the retina that eventually develops to some degree in nearly all patients with long-standing diabetes mellitus. While defects in neurosensory function have been demonstrated in patients with diabetes mellitus prior to the onset of vascular lesions, the earliest visible clinical manifestations of retinopathy include microaneurysms and hemorrhages. Vascular alterations can progress to retinal capillary nonperfusion, resulting in a clinical picture characterized by increased numbers of hemorrhages, venous abnormalities, and intraretinal microvascular abnormalities (IRMA). A later stage includes closure of arterioles and venules and proliferation of new vessels on the disc, retina, iris, and filtration angle. Increased vasopermeability results in retinal thickening (edema) during the course of diabetic retinopathy. Visual loss results mainly from macular edema, macular capillary nonperfusion, vitreous hemorrhage, and distortion or traction detachment of the retina.

A description of the fundus findings in various stages of diabetic retinopathy is included in the Natural History section. Important terms are defined in the Glossary.

PATIENT POPULATION

The patient population includes all patients with diabetes mellitus.

ACTIVITY

Evaluation and management of diabetes-related retinal disease.

PURPOSE

The primary purpose of evaluating and managing diabetic retinopathy is to prevent, retard, or reverse visual loss, thereby maintaining or improving vision-related quality of life.

GOALS

- Identify patients at risk of developing diabetic retinopathy
- Encourage involvement of the patient and primary care physician in the management of the patient's systemic disorder, with specific attention to control of blood sugar (hemoglobin A_{1c}), blood pressure, and serum lipids
- Encourage and provide lifelong evaluation of retinopathy progression
- Treat patients at risk for visual loss from diabetic retinopathy
- Minimize the side effects of treatment that might adversely affect the patient's vision and/or vision-related quality of life
- For patients with visual impairment from the disease, either provide visual rehabilitation services or refer the patient for such services

BACKGROUND

EPIDEMIOLOGY

For the purposes of this PPP, two forms of diabetes mellitus are recognized. Type 1, previously called juvenile-onset or insulin-dependent diabetes, is characterized by beta-cell destruction and usually leads to absolute insulin deficiency. Type 2, previously called adult-onset or noninsulin-dependent diabetes, is characterized by insulin resistance with an insulin secretory defect that leads to relative insulin deficiency.[1] Many patients with type 2 diabetes take insulin. Between 90% and 95% of patients with diabetes have type 2 diabetes. Because of the disproportionately large number

of patients with type 2 diabetes, this group comprises a substantial proportion of patients with visual impairment secondary to diabetic retinopathy, even though type 1 diabetes is associated with more frequent and more severe ocular complications.[2,3]

An estimated 19 million Americans aged 20 years or older have either diagnosed or undiagnosed diabetes mellitus; about one-third are not aware that they have the disease.[4] An additional 26% of adults (54 million persons) have impaired fasting blood glucose levels.[4] In the United States, an estimated three out of five people with diabetes have one or more of the complications associated with the disease.[5] Americans of African or Mexican descent have a disproportionately high prevalence of diabetes compared with Americans of European descent (11.0%, 10.4%, 5.2%, respectively).[4] An unusually high prevalence of diabetes is seen in Native American Indians and Alaskan Natives, with a prevalence rate of approximately 9% and a 46% increase in prevalence among those under age 35 years between 1990 and 1998.[6,7] An increase in the frequency of type 2 diabetes in the pediatric age group has been noted in several countries[3,8-12] and has been associated with the increased frequency of childhood obesity.[13] These trends predict an increase in the number of individuals with diabetes as well as associated increased costs for health care and the burdens of disability associated with diabetes and its complications.

Diabetic retinopathy is a leading cause of new cases of legal blindness among working-age Americans. The prevalence rate for retinopathy for adults aged 40 years and older in the United States is 3.4% (4.1 million persons); the prevalence rate for vision-threatening retinopathy is 0.75% (899,000 persons).[14] Assuming a similar prevalence of diabetes mellitus, the projected numbers in 2020 would be 6 million persons with diabetic retinopathy and 1.34 million persons with vision-threatening diabetic retinopathy.

RISK FACTORS

Duration of diabetes is a major risk factor associated with the development of diabetic retinopathy. After 5 years, approximately 25% of type 1 patients have retinopathy. After 10 years, almost 60% have retinopathy, and after 15 years, 80% have retinopathy.[15,16] In the Wisconsin Epidemiologic Study of Diabetic Retinopathy, proliferative diabetic retinopathy, the most vision-threatening form of the disease, was present in approximately 50% of type 1 patients with 20 years' duration of the disease.[17] In the Los Angeles Latino Eye Study and in Proyecto VER, about 18% of participants with diabetes of more than 15 years' duration had proliferative diabetic retinopathy.[16,18]

Of type 2 patients who have a known duration of diabetes of less than 5 years, 40% of those patients taking insulin and 24% of those not taking insulin have retinopathy. These rates increase to 84% and 53%, respectively, when the duration of diabetes has been documented for up to 19 years. Proliferative diabetic retinopathy develops in 2% of type 2 patients who have diabetes for less than 5 years and in 25% of patients who have diabetes for 25 years or more.[19] These percentages are based on data from the 1980s before there was closer monitoring and tighter glycemic control, and they may have improved.

The severity of hyperglycemia is the key alterable risk factor associated with the development of diabetic retinopathy. Support for this association is found in results of both clinical trials and epidemiologic studies.[20-26] There is general agreement that duration of diabetes and severity of hyperglycemia are the major risk factors for developing retinopathy. Once retinopathy is present, duration of diabetes appears to be a less important factor than hyperglycemia for progression from earlier to later stages of retinopathy.[27] Intensive management of hypertension has been demonstrated to slow retinopathy progression.[28,29] Elevated serum lipid levels are associated with the development of retinopathy.[30-32] There is less agreement among studies concerning the importance of other factors such as age, type of diabetes, clotting factors, renal disease, physical inactivity, and use of angiotensin-converting enzyme inhibitors.[27,31,33-35] Many of these factors are associated with the substantial cardiovascular morbidity and mortality and other complications associated with diabetes. Thus, it is reasonable to encourage patients with diabetes to be as compliant as possible with therapy of all medical aspects of their disease.[36]

NATURAL HISTORY

Diabetic retinopathy progresses in an orderly fashion from minimal changes to more severe stages if there is no intervention. It is important to recognize the stages in which treatment may be beneficial. Several decades of clinical research have provided excellent data on the natural course of the disease and on treatment strategies that are 90% effective in preventing the occurrence of severe vision loss.

These studies include the following major clinical trials: the Diabetes Control and Complications Trial (DCCT),[22,37,38] the Epidemiology of Diabetes Interventions and Complications (EDIC) trial (the follow-up epidemiology study of DCCT),[21,23,32,39] the Diabetic Retinopathy Study (DRS),[40-42] the Early Treatment Diabetic Retinopathy Study (ETDRS),[43-54] the Diabetic Retinopathy Vitrectomy Study (DRVS),[55-58] and the United Kingdom Prospective Diabetes Study (UKPDS).[24,28,59] The outcomes of these trials are solid foundations underlying the Preferred Practice Pattern for treating diabetic retinopathy. The results of these studies are presented in Appendices 3 and 4.

Diabetic retinopathy in its earliest clinically apparent stages is called nonproliferative diabetic retinopathy (NPDR) and is characterized by retinal vascular abnormalities including microaneurysms, intraretinal hemorrhages, and cotton-wool spots. Increased retinal vascular permeability that occurs at this or later stages of retinopathy may result in retinal thickening (edema) and lipid deposits (hard exudates). Clinically significant macular edema (CSME) is a term commonly used to describe retinal thickening and/or adjacent hard exudates that either involve the center of the macula or threaten to spread into it. Patients with CSME should be considered for focal laser photocoagulation, particularly if the center of the macula is already involved or if retinal thickening/adjacent hard exudates are very close to it (see Care Process).

As diabetic retinopathy progresses, there is a gradual closure of retinal vessels, which results in impaired perfusion and retinal ischemia. Signs of increasing ischemia include venous abnormalities (e.g., beading, loops), IRMA, and more severe and extensive vascular leakage characterized by increasing retinal hemorrhages and exudation. When these signs progress beyond certain defined thresholds, severe NPDR is diagnosed (see Glossary). Patients with this degree of retinopathy should be considered for possible treatment with panretinal (scatter) laser photocoagulation (see Care Process).

The more advanced stage, proliferative diabetic retinopathy (PDR), is characterized by the onset of neovascularization of the inner surface of the retina induced by the retinal ischemia. New vessels at the optic disc (NVD) and new vessels elsewhere in the retina (NVE) are prone to bleed, resulting in vitreous hemorrhage. These new vessels may undergo fibrosis and contraction; this and other fibrous proliferation may result in epiretinal membrane formation, vitreoretinal traction bands, retinal tears, and traction or rhegmatogenous retinal detachments. When new vessels are accompanied by vitreous hemorrhage, or when new vessels at the optic disc occupy greater than or equal to about one-quarter to one-third disc area, even in the absence of vitreous hemorrhage, PDR is said to be in the high-risk stage (see Glossary for definition of high-risk PDR). Neovascular glaucoma can result from new vessels growing on the iris (NVI) and anterior chamber angle structures. Patients with neovascular glaucoma or high-risk PDR should receive prompt panretinal photocoagulation (see Care Process).

Table 1 classifies diabetic retinopathy by severity based on clinical findings.

TABLE 1 DIABETIC RETINOPATHY DISEASE SEVERITY SCALE

Disease Severity Level	Findings Observable upon Dilated Ophthalmoscopy
No apparent retinopathy	No abnormalities
Mild NPDR	Microaneurysms only
Moderate NPDR	More than just microaneurysms but less than severe NPDR
Severe NPDR	Any of the following (4-2-1 rule) and no signs of proliferative retinopathy: • Severe intraretinal hemorrhages and microaneurysms in each of four quadrants • Definite venous beading in two or more quadrants • Moderate IRMA in one or more quadrants
PDR	One or both of the following: • Neovascularization • Vitreous/preretinal hemorrhage

IRMA = intraretinal microvascular abnormalities; NPDR = nonproliferative diabetic retinopathy; PDR = proliferative diabetic retinopathy

NOTE: Any patient with two or more of the characteristics of severe nonproliferative diabetic retinopathy is considered to have very severe nonproliferative diabetic retinopathy

In an attempt to improve communication worldwide between ophthalmologists and primary care physicians caring for patients with diabetes, an international clinical disease severity scale has been developed for diabetic retinopathy and macular edema (Tables 2 and 3).[60] This scale is based on the ETDRS classification of diabetic retinopathy and on the data collected in clinical trials and epidemiologic studies of diabetic retinopathy (see Appendix 5). Validation studies of the international scales are under way.

TABLE 2 INTERNATIONAL CLINICAL DIABETIC RETINOPATHY DISEASE SEVERITY SCALE

Proposed Disease Severity Level	Findings Observable upon Dilated Ophthalmoscopy
No apparent retinopathy	No abnormalities
Mild NPDR	Microaneurysms only
Moderate NPDR	More than just microaneurysms but less than severe NPDR
Severe NPDR	Any of the following and no signs of proliferative retinopathy: • More than 20 intraretinal hemorrhages in each of four quadrants • Definite venous beading in two or more quadrants • Prominent IRMA in one or more quadrants
PDR	One or both of the following: • Neovascularization • Vitreous/preretinal hemorrhage

IRMA = intraretinal microvascular abnormalities; NPDR = nonproliferative diabetic retinopathy; PDR = proliferative diabetic retinopathy

Reproduced with permission from Wilkinson CP, Ferris FL III, Klein RE, et al. Proposed international clinical diabetic retinopathy and diabetic macular edema disease severity scales. Ophthalmology 2003;110:1679.

TABLE 3 INTERNATIONAL CLINICAL DIABETIC MACULAR EDEMA DISEASE SEVERITY SCALE

Proposed Disease Severity Level	Findings Observable upon Dilated Ophthalmoscopy
Diabetic macular edema apparently absent	No apparent retinal thickening or hard exudates in posterior pole
Diabetic macular edema apparently present	Some apparent retinal thickening or hard exudates in posterior pole
If diabetic macular edema is present, it can be categorized as follows:	
Proposed Disease Severity Level	**Findings Observable upon Dilated Ophthalmoscopy***
Diabetic macular edema present	• Mild diabetic macular edema: some retinal thickening or hard exudates in posterior pole but distant from the center of the macula • Moderate diabetic macular edema: retinal thickening or hard exudates approaching the center of the macula but not involving the center • Severe diabetic macular edema: retinal thickening or hard exudates involving the center of the macula

* Hard exudates are a sign of current or previous macular edema. Diabetic macular edema is defined as retinal thickening; this requires a three-dimensional assessment that is best performed by dilated examination using slit-lamp biomicroscopy and/or stereoscopic fundus photography.

Reproduced with permission from Wilkinson CP, Ferris FL III, Klein RE, et al. Proposed international clinical diabetic retinopathy and diabetic macular edema disease severity scales. Ophthalmology 2003;110:1680.

PREVENTION AND EARLY DETECTION

Although a healthy lifestyle with exercise and weight control may decrease the risk of developing diabetes in some patients,[61,62] in many cases, diabetes cannot be prevented. In contrast, in many cases the blinding complications of diabetes mellitus can be prevented or moderated. Treatment can yield substantial cost savings compared with the direct costs for those disabled by vision loss (see Appendix 6). Analyses from two clinical trials show that the treatment for diabetic retinopathy may

be 90% effective in preventing severe vision loss (visual acuity less than 5/200) using current treatment strategies.[63] Although effective treatment is available, many fewer patients with diabetes are referred by their primary care physicians for ophthalmic care than would be expected according to guidelines by the American Diabetes Association and the American Academy of Ophthalmology.[64] In a community-based intervention trial, at enrollment 35% of participants did not follow the vision care guidelines; two-thirds of this group reported no eye examination in the year prior to enrollment and one-third had an undilated examination.[65] In the Los Angeles Latino Eye Study, 65% of those with type 2 diabetes had not received a dilated eye examination in the previous year.[66]

According to the National Committee for Quality Assurance's Health Plan Employers Data Information Set System, the average rate of annual eye examinations for patients with diabetes in participating health plans in 2007 was 55% for commercial health plans, 62% for Medicare plans, and 51% for Medicaid plans. Among prepaid health plan enrollees, 77% of patients with diabetes received an eye examination over a 3-year study period.[67] A longitudinal analysis of Medicare claims data for beneficiaries age 65 years or older found that 50% to 60% had annual eye examinations in a 15-month period.[68] Physicians who care for patients with diabetes and patients themselves need to be educated about indications for referral. Recommended intervals for eye examinations for patients with diabetes are provided in Table 4.

TABLE 4 RECOMMENDED EYE EXAMINATION SCHEDULE FOR PATIENTS WITH DIABETES MELLITUS

Diabetes Type	Recommended Time of First Examination	Recommended Follow-up*
Type 1	3-5 years after diagnosis[15] [A:II]	Yearly[15] [A:II]
Type 2	At time of diagnosis[19,69] [A:II]	Yearly[19,69] [A:II]
Prior to pregnancy (type 1 or type 2)	Prior to conception and early in the first trimester[70-72] [A:I]	No retinopathy to mild or moderate NPDR: every 3–12 months[70-72] [A:I] Severe NPDR or worse: every 1–3 months[70-72] [A:I]

NPDR = nonproliferative diabetic retinopathy

* Abnormal findings may dictate more frequent follow-up examinations.

The primary prevention and screening process for diabetic retinopathy varies according to the age of onset of the disease. Several forms of retinal screening with standard fundus photography or digital imaging, with and without dilation, are being investigated as a means of detecting retinopathy. Appropriately validated digital imaging technology can be a sensitive and effective screening tool to identify patients with diabetic retinopathy for referral for ophthalmic evaluation and management.[73] Some studies have found that photography is more sensitive in identifying sight-threatening retinopathy than clinical examination with ophthalmoscopy.[74-77] Digital cameras with stereoscopic capabilities are useful for identifying subtle neovascularization and macular edema.[78,79] At this time, it is not clear that photographic screening programs achieve a greater reduction in vision loss than does routine community care in areas where access to ophthalmologists is straightforward. Studies have found a positive association between participating in a photographic screening program and subsequent adherence to receiving recommended comprehensive dilated eye examinations by a clinician.[80,81] Of course, such screening programs have great value in circumstances in which access to ophthalmic care is limited.[82-85] Future research also should include establishing standardized protocols and satisfactory performance standards for diabetic retinopathy screening programs.

At this time, these technologies are not considered a replacement for a comprehensive eye evaluation by an ophthalmologist experienced in managing diabetic retinopathy.

Furthermore, ophthalmologists can play an important role in the total care of the patient with diabetes. For example, at the time of the eye examination, patients can be counseled about the importance of blood glucose and blood pressure control.

The DCCT showed that the development and progression of diabetic retinopathy in patients with type 1 diabetes can be delayed if glucose concentrations are maintained in the near-normal range (see Appendix 4).[22] After 3 years of intensive treatment to reduce glucose levels in patients without retinopathy, the development of any retinopathy was reduced by 75% over the 9-year course of the

study. Strict glucose control also resulted in a 50% reduction in the rate of progression of retinopathy in patients with existing retinopathy. At the 6- and 12-month visits, a small number of patients had a transient early worsening of the retinopathy in the intensive treatment group, but there was no effect on visual acuity. Beyond 3.5 years of follow-up, the risk of progression was five times lower with intensive insulin treatment than with conventional treatment and these benefits were maintained through the 10 years of the observational follow-up study of the DCCT cohort, the EDIC study.[86] The benefits of early intensive treatment on the progression of retinopathy persisted even as the differences in hemoglobin A_{1c} in the two former randomized treatment groups narrowed over the course of the EDIC study and became statistically insignificant by 5 years.

Evidence about the effects of controlling hyperglycemia in type 2 patients comes from observational data as well as randomized clinical trials. Definitive results were seen in the UKPDS,[24,87] a randomized, controlled clinical trial of blood glucose control in 3867 patients with newly diagnosed type 2 diabetes. Intensive blood glucose control by either the sulfonylureas or insulin decreased the risk of microvascular complications but not the risk of macrovascular disease. There were no adverse effects of the individual drugs on the cardiovascular outcome. In this study, there was a 29% reduction in the need for retinal photocoagulation surgery in the group with intensive glucose therapy compared with those receiving conventional treatment (relative risk, 0.71; 95% confidence interval, 0.53–0.96; P=0.003).

In the UKPDS, 1,148 patients with both diabetes and hypertension were randomly assigned to antihypertensive treatment.[28] Additional analyses from this nested trial of antihypertensive medications (captopril, an angiotensin-converting enzyme inhibitor, or atenolol, a beta-adrenergic antagonist) showed that tight blood pressure control achieved a clinically important reduction in the risk of deaths related to diabetes and in the risk of progression of diabetic retinopathy. There was a 34% reduction in the risk of progression of retinopathy from baseline by two or more steps by a median of 7.5 years (P=0.004) and a 47% reduced risk of decreased vision by three lines on the ETDRS chart (P=0.004). There was no difference in the progression of retinopathy or the final visual acuity in those patients treated with an angiotensin-converting enzyme inhibitor compared with those treated with a beta-adrenergic antagonist.

It is important to educate all patients who have diabetes about the disease and to emphasize the value of maintaining blood glucose (as monitored by hemoglobin A_{1c}) as near normal as is safely possible. The EDIC studies have shown that lowering blood glucose reduces other end-organ complications as well, including nephropathy and neuropathy and cardiovascular disease (see Appendix 4). The results of the UKPDS demonstrate the value of controlling blood glucose and blood pressure in all patients with type 2 diabetes.

Medical treatment such as aspirin therapy has been evaluated for the prevention and retardation of diabetic retinopathy. The ETDRS found no evidence that aspirin therapy at a dose of 650 mg per day retards or accelerates the progression of diabetic retinopathy[45] or that it causes more severe or more long-lasting vitreous hemorrhages in patients with PDR.[88]

CARE PROCESS

The care process for diabetic retinopathy includes a medical history, an ophthalmic examination, and vigilant follow-up. Early detection of retinopathy depends on educating patients with diabetes as well as their families, friends, and health care providers about the importance of regular eye examination even though the patient may be asymptomatic. Adults with diabetes mellitus without diabetic retinopathy should be encouraged to have annual dilated eye examinations to detect the onset of diabetic retinopathy.[15,19 [A:II]] Children with diabetes mellitus without diabetic retinopathy should have annual dilated eye examinations 5 years after the onset of diabetes.[15,89,90 [A:II]] Patients should also be informed that effective treatment for diabetic retinopathy depends on timely intervention, despite good vision and no ocular symptoms.[A:III] (The recommended timing of the first ophthalmic examination and subsequent follow-up examinations for patients with diabetes is listed in Table 4 and described in the section Examination Schedule.)

Maintaining near-normal glucose levels and near-normal blood pressure lessens the risk of retinopathy developing and progressing[21,22,24,28,87 [A:I]]; patients should be informed of the importance of maintaining good glucose control and monitoring serum glycosylated hemoglobin levels.[A:III]

Aspirin may be used without concern for worsening diabetic retinopathy by patients with diabetes who require aspirin for other medical indications and have no contraindications.[45,88 [A:I]]

PATIENT OUTCOME CRITERIA

Patient outcome criteria include the following:

- Improvement or stabilization of visual function
- Improvement or stabilization of vision-related quality of life
- Coordination of care management to achieve optimal glycemic control

DIAGNOSIS

The initial examination for a patient with diabetes mellitus includes all features of the comprehensive adult medical eye evaluation,[91] with particular attention to those aspects relevant to diabetic retinopathy.

History

An initial history should consider the following elements:

- Duration of diabetes[15,27,92 [A:I]]
- Past glycemic control (hemoglobin A_{1c})[27,38,92 [A:I]]
- Medications[[A:III]]
- Medical history (e.g., obesity,[[A:III]] renal disease,[15,19 [A:II]] systemic hypertension,[15,19 [A:I]] serum lipid levels,[93 [A:II]] pregnancy[70,71 [A:I]])
- Ocular history[[A:III]] (e.g., trauma, ocular injections, surgery, including laser treatment and refractive surgery)

Examination

The initial examination should include the following elements:

- Visual acuity[43 [A:I]]
- Slit-lamp biomicroscopy[[A:III]]
- Intraocular pressure[[A:III]]
- Gonioscopy when indicated[[A:III]]
- Dilated funduscopy including stereoscopic examination of the posterior pole[51 [A:I]]
- Examination of the peripheral retina and vitreous[[A:III]]

Iris neovascularization may be recognized best prior to dilation. If neovascularization of the iris is present or suspected, or if the intraocular pressure is elevated, gonioscopy can be used to detect neovascularization of the anterior chamber angle. A dilated pupil is necessary to ensure optimal examination of the retina, because only 50% of eyes are correctly classified for the presence and severity of retinopathy through undilated pupils.[94 [A:I]] Slit-lamp biomicroscopy with accessory lenses is the recommended method to evaluate retinopathy in the posterior pole and midperipheral retina.[51 [A:III]] The examination of the peripheral retina is best performed with indirect ophthalmoscopy or with slit-lamp biomicroscopy, combined with a contact lens.[[A:III]]

Because treatment is effective in reducing the risk of visual loss, detailed examination is indicated to assess for the following features that often lead to visual impairment:

- Presence of macular edema
- Optic nerve head neovascularization and/or neovascularization elsewhere
- Signs of severe NPDR (extensive retinal hemorrhages/microaneurysms, venous beading, and IRMA)
- Vitreous or preretinal hemorrhage

Examination Schedule

Type 1 (Diabetes Onset Usually Before Age 30 Years)

Many studies of patients with type 1 diabetes have reported a direct relationship between the prevalence and severity of retinopathy and the duration of diabetes.[19,95-97] The development of vision-threatening retinopathy is rare in children prior to puberty.[95,98] Among patients with type 1

diabetes, substantial retinopathy may become apparent as early as 6 to 7 years after onset of the disease.[15] Ophthalmic examinations should be performed beginning 3 to 5 years after the diagnosis of type 1 diabetes and will discover the vast majority of type 1 patients who require therapy at that time.[15,89 [A:II]]

Type 2 (Diabetes Onset Usually at Age 30 Years or Older)

The time of onset of type 2 diabetes is often difficult to determine and may precede the diagnosis by a number of years.[99] Up to 3% of patients whose diabetes is first diagnosed at age 30 or later will have CSME or high-risk characteristics at the time of the initial diagnosis of diabetes.[15] About 30% of patients will have some manifestation of diabetic retinopathy at diagnosis. Therefore, the patient should be referred for ophthalmologic examination at the time of diagnosis.[19,69 [A:II]]

Diabetes Associated with Pregnancy

Diabetic retinopathy can worsen during pregnancy because of the pregnancy itself or changes in metabolic control.[70-72] Patients with diabetes who are planning to become pregnant should be encouraged to have their eyes examined prior to conception, should be counseled on the risk of development and/or progression of diabetic retinopathy, and should be told to make every attempt to lower their blood glucose levels to as near normal as possible for their own health and the health of the fetus.[70-72 [A:I]] During the first trimester, another eye examination should be performed; subsequent follow-up will depend on the level of retinopathy found (see Table 4). Women who develop gestational diabetes do not require an eye examination during pregnancy, because such individuals are not at increased risk for diabetic retinopathy during pregnancy.

After the examination is completed, the ophthalmologist should discuss the results and their implications with the patient.[A:III] Both eyes should be classified according to the categories of diabetic retinopathy and macular edema discussed in the Treatment section.[A:III] Each category has an inherent risk for progression. The diagnostic category determines the timing for both the intervention and for follow-up examinations.

Ancillary Tests

If used appropriately, a number of tests ancillary to the clinical examination may enhance patient care. The most common tests include the following:

- Color fundus photography
- Optical coherence tomography
- Fluorescein angiography
- Ultrasonography

Color Fundus Photography

Fundus photography is a more reproducible technique than a clinical examination for detecting diabetic retinopathy in clinical research studies. However, clinical examination is often superior for detecting retinal thickening associated with macular edema and may be better at identifying fine-caliber NVD or NVE.

Fundus photography is seldom of value in cases of minimal diabetic retinopathy or when diabetic retinopathy is unchanged from the previous photographic appearance.[A:III] Fundus photography may be useful for documenting substantial progression of disease and response to treatment.[B:III]

Optical Coherence Tomography

Optical coherence tomography provides high-resolution (10 microns) imaging of the vitreoretinal interface, retina, and subretinal space. Optical coherence tomography can be useful for quantifying retinal thickness, monitoring macular edema, and identifying vitreomacular traction in selected patients with diabetic macular edema.[100-104] However, optical coherence tomography measures of retinal thickness correlate poorly with visual acuity.[105]

Fluorescein Angiography

Fluorescein angiography is a clinically valuable test for selected patients with diabetic retinopathy and is commonly used as a guide for treating CSME[51 [A:I]] and as a means of evaluating the cause(s) of unexplained decreased visual acuity[A:III] (see Table 5). Angiography can identify macular

capillary nonperfusion[54 [A:II]] or sources of capillary leakage resulting in macular edema as possible explanations for visual loss.

Fluorescein angiography is not routinely indicated as a part of the examination of patients with diabetes.[A:III] It is not needed to diagnose CSME or PDR, both of which are diagnosed by means of the clinical examination. However, because the test is useful in various situations, facilities for fluorescein angiography should be available to physicians who diagnose and treat patients with diabetic retinopathy.

TABLE 5 USE OF FLUORESCEIN ANGIOGRAPHY FOR DIABETIC RETINOPATHY

Situation	Usually	Occasionally	No
To guide treatment of CSME	◆		
To evaluate unexplained visual loss	◆		
To identify suspected but clinically obscure retinal neovascularization		◆	
To screen a patient with no or minimal diabetic retinopathy			◆

CSME = clinically significant macular edema

An ophthalmologist who orders fluorescein angiography must be aware of the potential risks associated with the procedure; severe medical complications may occur, including death (about 1/200,000 patients).[106] Each angiography facility should have in place a care plan or emergency plan and a clear protocol to minimize the risks and to manage any complications.[A:III] Although detrimental effects of fluorescein dye on the fetus have not been documented, fluorescein dye does cross the placenta into the fetal circulation.[107]

Ultrasonography

Ultrasonography is a valuable test to detect retinal detachment in diabetic eyes with opaque media (most commonly due to cataract or vitreous hemorrhage).

TREATMENT

Laser photocoagulation surgery is the standard technique for treating diabetic retinopathy. In general, it is advised for patients with high-risk PDR, CSME, or neovascularization of the anterior chamber angle (Table 6).[40,52,108 [A:I]] Individuals who are treated according to methods used in the DRS and ETDRS have better visual outcomes than those who are not treated.[40,43] Regardless of the wavelength used, it is important to avoid excessively intense burns, especially for focal laser photocoagulation. Vitrectomy is also an important part of the treatment strategies for advanced diabetic retinopathy. Vitrectomy for PDR has been shown to increase vision-related quality of life.[109]

Laser photocoagulation techniques can be classified as panretinal, focal, or grid (see also Glossary). Panretinal photocoagulation, also referred to as scatter photocoagulation,[53] is used for the treatment of proliferative diabetic retinopathy and indirectly treats neovascularization of the optic nerve, retinal surfaces, or in the anterior chamber angle by placing laser burns throughout the peripheral fundus. It may be done in more than one session. Focal and grid photocoagulation are used for the treatment of diabetic macular edema. Focal photocoagulation applies light, small-sized burns to leaking microaneurysms in the macula (outside the foveal avascular zone). Grid photocoagulation applies a grid or pattern of burns (mimicking panretinal photocoagulation but using smaller burns) to the areas of macular edema arising from diffuse capillary leakage or nonperfusion shown on fluorescein angiography.[54] Retrobulbar or peribulbar injections can be used with laser photocoagulation techniques. Serious complications of retrobulbar or peribulbar injections are rare, but they do occur.[110] The ETDRS protocol provides detailed guidelines for laser photocoagulation treatment.[52,53 [A:I]]

Management recommendations for patients with diabetes are summarized in Table 6 and are described according to the severity of retinopathy in the following pages. The table provides guidance for a preferred practice pattern for the general population of patients with diabetes; specific needs may vary on a case-by-case basis. Table 7 lists side effects and complications of treatment.

Normal or Minimal NPDR

The patient with a normal retinal exam or minimal NPDR (i.e., with rare microaneurysms) should be re-examined annually,[15 [A:II]] because within 1 year 5% to 10% of patients who are initially

normal will develop diabetic retinopathy. Existing retinopathy will worsen by a similar percentage.[33,34,37] Laser surgery, color fundus photography, and fluorescein angiography are not indicated. [A:III]

Mild to Moderate NPDR Without Macular Edema

Patients with retinal microaneurysms and occasional blot hemorrhages or hard exudates should have a repeat examination within 6 to 12 months, because disease progression is common.[33] [A:III] In one study of type 1 patients, 16% of patients with mild retinopathy (hard exudates and microaneurysms only) progressed to proliferative stages within 4 years.[33]

Laser surgery and fluorescein angiography are not indicated for this group of patients. Color fundus photography may occasionally be helpful as a baseline for future comparison (see Ancillary Tests section).

For patients with mild NPDR, the 4-year incidence of either CSME or macular edema that is not clinically significant is 12%. For moderate NPDR, the risk increases to 23% for patients with types 1 and 2 diabetes.[43] Patients with macular edema that is not clinically significant should be re-examined within 3 to 4 months, because they are at risk of developing CSME.[51] [A:I]

TABLE 6 MANAGEMENT RECOMMENDATIONS FOR PATIENTS WITH DIABETES

Severity of Retinopathy	Presence of CSME*	Follow-up (Months)	Panretinal Photocoagulation (Scatter) Laser	Fluorescein Angiography	Focal and/or Grid Laser†
Normal or minimal NPDR	No	12	No	No	No
Mild to moderate NPDR	No	6-12	No	No	No
	Yes	2-4	No	Usually	Usually*‡
Severe NPDR	No	2-4	Sometimes§	Rarely	No
	Yes	2-4	Sometimes§	Usually	Usually‖
Non-high-risk PDR	No	2-4	Sometimes§	Rarely	No
	Yes	2-4	Sometimes§	Usually	Usually‡
High-risk PDR	No	2-4	Usually	Rarely	No
	Yes	2-4	Usually	Usually	Usually‖
Inactive/involuted PDR	No	6-12	No	No	Usually
	Yes	2-4	No	Usually	Usually

CSME = clinically significant macular edema; NPDR = nonproliferative diabetic retinopathy; PDR = proliferative diabetic retinopathy

* Exceptions include hypertension or fluid retention associated with heart failure, renal failure, pregnancy, or any other causes that may aggravate macular edema. Deferral of photocoagulation for a brief period of medical treatment may be considered in these cases.[111] Also, deferral of CSME treatment is an option when the center of the macula is not involved, visual acuity is excellent, close follow-up is possible, and the patient understands the risks.

† Adjunctive treatments that may be considered include intravitreal corticosteroids or anti-vascular endothelial growth factor agents (off-label use except ranibizumab). Data from the Diabetic Retinopathy Clinical Research Network in 2011 demonstrated that, at two years of follow-up, intravitreal ranibizumab with prompt or deferred laser resulted in greater visual acuity gain and intravitreal triamcinolone acetonide plus laser also resulted in greater visual gain in pseudophakic eyes compared with laser alone.[112] Individuals receiving the intravitreal injections of anti-vascular endothelial growth factor agents may be examined one month following injection.

‡ Deferring focal photocoagulation for CSME is an option when the center of the macula is not involved, visual acuity is excellent, close follow-up is possible, and the patient understands the risks. However, initiation of treatment with focal photocoagulation should also be considered because although treatment with focal photocoagulation is less likely to improve the vision, it is more likely to stabilize the current visual acuity. Treatment of lesions close to the foveal avascular zone may result in damage to central vision and with time, such laser scars may expand and cause further vision deterioration. Future studies may help guide the use of intravitreal therapies including corticosteroids and anti-vascular endothelial growth factor agents in these cases in which laser photocoagulation cannot be safely administered. Closer follow-up may be necessary for macular edema that is not clinically significant.

§ Panretinal photocoagulation surgery may be considered as patients approach high-risk PDR. The benefit of early panretinal photocoagulation at the severe nonproliferative or worse stage of retinopathy is greater in patients with type 2 diabetes than in those with type 1.[113] Treatment should be considered for patients with severe NPDR and type 2 diabetes. Other factors, such as poor compliance with follow-up, impending cataract extraction or pregnancy, and status of the fellow eye will help in determining the timing of the panretinal photocoagulation.

‖ It is preferable to perform focal photocoagulation first, prior to panretinal photocoagulation, to minimize panretinal photocoagulation laser–induced exacerbation of the macular edema.

TABLE 7 SIDE EFFECTS AND COMPLICATIONS OF TREATMENT FOR DIABETIC RETINOPATHY

Treatment	Side Effect/Complication
Focal laser photocoagulation for diabetic macular edema	Initial decrease in central vision Paracentral scotomas if laser burns have been placed close to the fovea, especially large or confluent burns[114] Permanent central scotoma from inadvertent foveal burns
Panretinal photocoagulation (scatter) for severe NPDR or PDR	Central vision loss from macular edema[43] Peripheral visual field constrictions with poor dark adaptation Vitreous hemorrhage if neovascularization is present Loss of accommodation[115]
Vitrectomy	Recurrent vitreous hemorrhage[116] Retinal detachment[117] Rubeosis iridis[118] Severe visual loss[117,119] Microbial endophthalmitis[120] Cataract[121]
Intravitreal injections	Cataract progression with intravitreal corticosteroid administration[122,123] Elevated intraocular pressure with intravitreal corticosteroid administration[122,123] Infectious endophthalmitis Transient sterile inflammatory reactions Possible systemic effect from intravitreal medication

NPDR = nonproliferative diabetic retinopathy; PDR = proliferative diabetic retinopathy

Mild to Moderate NPDR with CSME

Clinically significant macular edema is defined by the ETDRS to include any of the following features:

- Thickening of the retina at or within 500 microns of the center of the macula, that is approximately one-half optic disc diameter
- Hard exudates at or within 500 microns of the center of the macula, if associated with thickening of the adjacent retina (not residual hard exudates remaining after the disappearance of retinal thickening)
- A zone or zones of retinal thickening one disc area or larger, any part of which is within one disc diameter of the center of the macula

It is convenient to subdivide CSME according to involvement at the center of the macula, because the risk of visual loss and the need for focal photocoagulation is greater when the center is involved. The diagnosis of diabetic macular edema can be difficult. Macular edema is best evaluated by dilated examination using slit-lamp biomicroscopy, optical coherence tomography, and/or stereoscopic fundus photography. An ophthalmologist who treats patients for this condition should be familiar with relevant studies and techniques as described in the ETDRS.[51,54 [A:I]] Fluorescein angiography prior to laser surgery for CSME is often helpful for identifying treatable lesions (although it is less important when there are circinate lipid exudates in which leaking lesions are often obvious within the lipid ring) and for identifying pathologic enlargement of the foveal avascular zone, which may be useful in planning treatment.[51 [A:I]] Color fundus photography is often helpful to document the status of the retina even if surgery is not performed (see Ancillary Tests section). Optical coherence tomography is helpful to detect subtle edema and to follow the course of edema after treatment, but is not necessary as a screening tool.

The treatment of CSME has traditionally been laser surgery; more recently data from the Diabetic Retinopathy Clinical Research Network (DRCR.net) and other studies have demonstrated that intravitreal antivascular endothelial growth factor agents are effective treatments for CSME.[51,54,112,124-129 [A:I]] The visual acuity gain and reduction in macular thickness following the administration of the combination of intravitreal ranibizumab, with prompt or deferred laser were greater than laser alone at two years of follow-up. Studies suggest that intravitreal corticosteroids

may play an important role in the treatment of CSME. In the DRCR.net study, the combination of intravitreal triamcinolone acetonide and laser photocoagulation resulted in greater visual gain in pseudophakic eyes at one year. The ETDRS results showed the risk of moderate visual loss (i.e., doubling of the visual angle; for example, a visual acuity decrease from 20/40 to 20/80) is reduced by more than 50% for patients who undergo appropriate laser photocoagulation surgery, compared with those who are not treated (see Appendix 3). However, vision improves for only a minority of patients; for the majority of cases, the goal of treatment with laser photocoagulation is to stabilize the visual acuity. The strategy for the treatment of CSME will evolve as the DRCR.net study reports longer follow-up and data from similar studies will help to define the frequency, duration of therapy, and the appropriate combination of treatments.

When treatment for macular edema is deferred, as may be desirable when the center of the macula is not involved or imminently threatened, the patient should be observed closely (at least every 3 to 4 months) for progression.[A:III]

Rarely, focal laser photocoagulation may induce subretinal fibrosis with choroidal neovascularization, which may be associated with permanent central vision loss.[130-132] The most important factors associated with subretinal fibrosis include the most severe degree of subretinal hard exudates in the macula and elevated serum lipids prior to laser photocoagulation.[133] Only 8% of cases of subretinal fibrosis were directly related to focal laser photocoagulation.

Effective laser treatment and retreatment protocols have been detailed in the DRS and the ETDRS.[40,52,53] Preoperatively, the ophthalmologist should discuss with the patient the side effects and risks of treatment.[51,54 [A:I]] A follow-up examination for individuals with CSME should be scheduled within 2 to 4 months of laser surgery[51 [A:II]] while individuals receiving the intravitreal injections of anti-vascular endothelial growth factor agents may be examined one month following therapy (see Table 6). Adverse effects associated with the intravitreal injections include infectious endophthalmitis and specifically, cataract development and elevated intraocular pressure for triamcinolone (See Table 7).

There have been case reports of idiosyncratic occurrences of macular edema temporally associated with the use of the glitazone class of oral antihyperglycemic agents.[134,135]

Multiple case series have indicated that pars plana vitrectomy to manage selected patients with diffuse CSME that is unresponsive to previous macular laser photocoagulation may improve visual acuity when substantial vitreomacular traction is present.[136-138] However, the value of vitrectomy in CSME has not been studied in a randomized clinical trial.

Severe NPDR and Non-High-Risk PDR

These categories are combined for discussion because the ETDRS data showed that they have a similar clinical course and subsequent recommendations for treatment are similar. In eyes with severe NPDR, the risk of progression to proliferative disease is high. Half of patients with severe NPDR will develop PDR within 1 year, and 15% will be high-risk PDR.[43] For patients with very severe NPDR, the risk of developing PDR within 1 year is 75%, and 45% will be high-risk PDR. Therefore, these patients should be re-examined within 2 to 4 months.[43,113 [A:I]] Refer to Table 1 for the definition of severe NPDR and very severe NPDR.

The ETDRS compared early panretinal photocoagulation with deferral of photocoagulation, defined as careful follow-up (at 4-month intervals) and prompt panretinal photocoagulation if progression to high-risk PDR occurred (see Appendix 3). Although the study did not provide definitive guidelines, the ETDRS suggested that panretinal photocoagulation should not be recommended for eyes with mild or moderate NPDR, provided that follow-up could be maintained. When retinopathy is more severe, panretinal photocoagulation should be considered and usually should not be delayed if the eye has reached the high-risk proliferative stage (see Appendix 3).[43 [A:I]] Careful follow-up at 3 to 4 months is important: if the patient will not or cannot be followed closely or if there are associated medical conditions such as impending cataract surgery or pregnancy, then early laser photocoagulation may be indicated.[43,113 [A:I]] Laser photocoagulation may be indicated particularly when access to health care is difficult. If laser surgery is elected, full panretinal photocoagulation is a proven surgical technique, but partial panretinal photocoagulation is not recommended.[40 [A:I]]

Additional analyses of visual outcome in ETDRS patients with severe NPDR to non-high-risk PDR suggest that the recommendation to consider panretinal photocoagulation before the development of high-risk PDR is particularly appropriate for patients with type 2 diabetes. The risk of severe vision

loss or vitrectomy was reduced by 50% (2.5% vs. 5%, $P = 0.0001$) in patients with type 2 diabetes who were treated early compared with deferral until high-risk PDR developed.[113] For patients with type 1 diabetes, the timing of the panretinal photocoagulation will depend on the compliance with follow-up and the status and response to treatment of the fellow eye. For both patients with type 1 and type 2 diabetes, impending or recent cataract surgery or pregnancy may increase the risk of progression and may influence the decision to perform panretinal photocoagulation.

The goal of laser surgery is to reduce the risk of visual loss. Preoperatively, the ophthalmologist should assess macular edema, discuss side effects of treatment and risks of visual loss with the patient, and obtain informed consent.[52,53 [A:I]]

When panretinal photocoagulation for severe NPDR or non-high-risk PDR is to be carried out in eyes with macular edema, many experts feel that it is preferable to perform focal photocoagulation before panretinal photocoagulation. Based on clinical trials, there is evidence that panretinal photocoagulation as used in the DRS and ETDRS may exacerbate macular edema and may cause increased rates of moderate visual loss (i.e., doubling of the visual angle) compared with untreated control eyes.[43] Panretinal photocoagulation laser surgery should not be delayed, however, if PDR is well into the high-risk stage (i.e., if NVD is extensive or vitreous/preretinal hemorrhage has occurred recently). In such cases, focal and panretinal photocoagulation may be performed concomitantly.

Fluorescein angiography may be used to determine the presence or absence of areas of nonperfusion and/or clinically undetected areas of retinal neovascularization and to establish the cause of a documented loss of visual acuity.

High-Risk PDR

The Diabetic Retinopathy Study high-risk characteristics for severe visual loss with high-risk PDR include the following:

- New vessels within one disc diameter of the optic nerve head that are larger than one-third disc area
- Vitreous or preretinal hemorrhage associated with less extensive NVD or with NVE one-half disc area or more in size

The risk of severe visual loss among patients with high-risk PDR can be reduced substantially by means of panretinal photocoagulation as described in the DRS and ETDRS. Most patients with high-risk PDR should receive laser panretinal photocoagulation treatment expeditiously.[40,42 [A:I]] Panretinal photocoagulation usually causes some degree of regression of neovascularization. This technique has been fully described[40,53] and the results are summarized in Appendix 3. Additional panretinal photocoagulation or vitrectomy may be required for increasing neovascularization of the iris and may be considered for the following indications:

- Failure of the neovascularization to regress
- Increasing neovascularization of the retina or iris
- New vitreous hemorrhage
- New areas of neovascularization

For patients who have CSME in addition to high-risk PDR, combined focal and panretinal photocoagulation at the first treatment session should be considered. Fluorescein angiography does not usually need to be performed in order to apply the panretinal photocoagulation effectively. If CSME is present, however, a fluorescein angiogram may be used to guide application of focal photocoagulation. In some cases, vitreous hemorrhage may recur in patients who have had extensive panretinal photocoagulation. These hemorrhages may clear spontaneously and do not necessarily require additional laser surgery.

Some patients with previously untreated PDR who have vitreous opacities and active proliferation of neovascularization (e.g., rubeosis iridis) should have early vitrectomy.[55-58 [A:II]] Vitrectomy also may be helpful for selected patients who have extensive active neovascular or fibrovascular proliferation. The value of early vitrectomy tends to increase with the increasing severity of neovascularization (see Appendix 3).

High-Risk PDR Not Amenable to Photocoagulation

In some patients with severe vitreous or preretinal hemorrhage, it may be impossible to perform laser photocoagulation surgery. In other cases, advanced active PDR may persist despite extensive panretinal photocoagulation. In some of these cases, vitreous surgery may be indicated. Vitreous

surgery is frequently indicated in patients with traction macular detachment (particularly of recent onset), combined traction–rhegmatogenous retinal detachment, and vitreous hemorrhage precluding panretinal photocoagulation. Patients with vitreous hemorrhage and rubeosis iridis also should be considered for prompt vitrectomy and intraoperative panretinal photocoagulation surgery.

Other Treatments

A number of studies are under way to evaluate other treatments for diabetic retinopathy. As described above, these include intravitreal administration of short- and long-acting corticosteroids for the treatment of diabetic macular edema. An earlier Diabetic Retinopathy Clinical Research Network study evaluated the role of intravitreal triamcinolone acetonide against focal laser photocoagulation. Treatment with intravitreal triamcinolone acetonide resulted in early decrease in retinal thickness at 4 months, but by 24 months those patients randomized to focal/grid laser photocoagulation had better mean visual acuity and fewer adverse effects of cataract development and elevation of intraocular pressure. This study design, however, did not evaluate the role of intravitreal corticosteroids plus standard focal/grid laser photocoagulation compared with laser photocoagulation alone.[139] Subsequent study showed increased visual gain in pseudophakic eyes that were given the combination of the intravitreal triamcinolone acetonide and laser.[112,126] A study of peribulbar (anterior and posterior sub-Tenon) injection of triamcinolone acetonide alone or in combination with focal/grid photocoagulation showed no large beneficial effect of peribulbar corticosteroid injections and significant adverse side effects as late as two years following treatment.[140] Additional studies will help determine the treatment strategies that may be beneficial for persons with diabetic macular edema.

FOLLOW-UP

The follow-up evaluation includes a history and examination.

History

A follow-up history should include changes in the following:

- Symptoms[A:III]
- Systemic status (pregnancy, blood pressure, serum cholesterol, renal status)[A:III]
- Glycemic status (hemoglobin A_{1c})[27,38,92 A:I]

Examination

A follow-up examination should include the following elements:

- Visual acuity[43 A:I]
- Slit-lamp biomicroscopy with iris examination[141 A:II]
- Intraocular pressure[A:III]
- Gonioscopy (if iris neovascularization is suspected or present or if intraocular pressure is increased)[141 A:II]
- Stereoscopic examination of the posterior pole after dilation of the pupils[51 A:I]
- Peripheral retina and vitreous examination, when indicated[48 A:II]

Recommended intervals for follow-up are given in Table 6.

PROVIDER

Although the ophthalmologist will perform most of the examination and all surgery, certain aspects of data collection may be conducted by other trained individuals under the ophthalmologist's supervision and review. Because of the complexities of the diagnosis and surgery for PDR, the ophthalmologist caring for patients with this condition should be familiar with the specific recommendations of the DRS, ETDRS, UKPDS, and DCCT/EDIC (see Appendices 3 and 5).[A:III] The ophthalmologist should also have training in and experience with the management of this particular condition.[A:III]

PHYSICIAN QUALITY REPORTING SYSTEM

The Physician Quality Reporting System program, initially launched by the Centers for Medicare and Medicaid Services in July 2007, encourages quality improvement through the use of clinical performance measures on a variety of clinical conditions. Measures in the 2012 program for diabetic

eye care are a dilated eye examination, documentation of the level of severity of retinopathy and the presence or absence of macular edema, and communication of examination results to the physician managing ongoing diabetes care.[142]

COUNSELING/REFERRAL

The ophthalmologist should refer patients with diabetes who do not have a primary care physician for appropriate management of their systemic condition.[A:III] The ophthalmologist should communicate examination results to the physician who is managing ongoing diabetes care.[A:III] An Eye MD Examination Report Form is available from the American Academy of Ophthalmology.[143]

Some patients with diabetic retinopathy will lose substantial vision despite being treated according to the recommendations in this document.[113] Those whose conditions fail to respond to surgery and those for whom further treatment is unavailable should be provided with proper professional support and offered referral for counseling, vision rehabilitation, or social services as appropriate.[144 [A:III]] Vision rehabilitation restores functional ability[145 [A:I]] and patients with functionally limiting postoperative visual impairment should be referred for vision rehabilitation and social services.[144 [A:III]] More information on vision rehabilitation, including materials for patients, is available at www.aao.org/smartsight.

APPENDIX 1. QUALITY OF OPHTHALMIC CARE CORE CRITERIA

Providing quality care
is the physician's foremost ethical obligation, and is
the basis of public trust in physicians.
AMA Board of Trustees, 1986

Quality ophthalmic care is provided in a manner and with the skill that is consistent with the best interests of the patient. The discussion that follows characterizes the core elements of such care.

The ophthalmologist is first and foremost a physician. As such, the ophthalmologist demonstrates compassion and concern for the individual, and utilizes the science and art of medicine to help alleviate patient fear and suffering. The ophthalmologist strives to develop and maintain clinical skills at the highest feasible level, consistent with the needs of patients, through training and continuing education. The ophthalmologist evaluates those skills and medical knowledge in relation to the needs of the patient and responds accordingly. The ophthalmologist also ensures that needy patients receive necessary care directly or through referral to appropriate persons and facilities that will provide such care, and he or she supports activities that promote health and prevent disease and disability.

The ophthalmologist recognizes that disease places patients in a disadvantaged, dependent state. The ophthalmologist respects the dignity and integrity of his or her patients, and does not exploit their vulnerability.

Quality ophthalmic care has the following optimal attributes, among others.

- The essence of quality care is a meaningful partnership relationship between patient and physician. The ophthalmologist strives to communicate effectively with his or her patients, listening carefully to their needs and concerns. In turn, the ophthalmologist educates his or her patients about the nature and prognosis of their condition and about proper and appropriate therapeutic modalities. This is to ensure their meaningful participation (appropriate to their unique physical, intellectual and emotional state) in decisions affecting their management and care, to improve their motivation and compliance with the agreed plan of treatment, and to help alleviate their fears and concerns.
- The ophthalmologist uses his or her best judgment in choosing and timing appropriate diagnostic and therapeutic modalities as well as the frequency of evaluation and follow-up, with due regard to the urgency and nature of the patient's condition and unique needs and desires.
- The ophthalmologist carries out only those procedures for which he or she is adequately trained, experienced and competent, or, when necessary, is assisted by someone who is, depending on the urgency of the problem and availability and accessibility of alternative providers.
- Patients are assured access to, and continuity of, needed and appropriate ophthalmic care, which can be described as follows.
  - The ophthalmologist treats patients with due regard to timeliness, appropriateness and his or her own ability to provide such care.
  - The operating ophthalmologist makes adequate provision for appropriate pre- and postoperative patient care.
  - When the ophthalmologist is unavailable for his or her patient, he or she provides appropriate alternate ophthalmic care, with adequate mechanisms for informing patients of the existence of such care and procedures for obtaining it.
  - The ophthalmologist refers patients to other ophthalmologists and eye care providers based on the timeliness and appropriateness of such referral, the patient's needs, the competence and qualifications of the person to whom the referral is made, and access and availability.
  - The ophthalmologist seeks appropriate consultation with due regard to the nature of the ocular or other medical or surgical problem. Consultants are suggested for their skill, competence and accessibility. They receive as complete and accurate an accounting of the problem as necessary to provide efficient and effective advice or intervention, and in turn respond in an adequate and timely manner.
  - The ophthalmologist maintains complete and accurate medical records.

- On appropriate request, the ophthalmologist provides a full and accurate rendering of the patient's records in his or her possession.
- The ophthalmologist reviews the results of consultations and laboratory tests in a timely and effective manner and takes appropriate actions.
- The ophthalmologist and those who assist in providing care identify themselves and their profession.
- For patients whose conditions fail to respond to treatment and for whom further treatment is unavailable, the ophthalmologist provides proper professional support, counseling, rehabilitative and social services, and referral as appropriate and accessible.

- Prior to therapeutic or invasive diagnostic procedures, the ophthalmologist becomes appropriately conversant with the patient's condition by collecting pertinent historical information and performing relevant preoperative examinations. Additionally, he or she enables the patient to reach a fully informed decision by providing an accurate and truthful explanation of the diagnosis; the nature, purpose, risks, benefits, and probability of success of the proposed treatment and of alternative treatment; and the risks and benefits of no treatment.
- The ophthalmologist adopts new technology (e.g., drugs, devices, surgical techniques) in judicious fashion, appropriate to the cost and potential benefit relative to existing alternatives and to its demonstrated safety and efficacy.
- The ophthalmologist enhances the quality of care he or she provides by periodically reviewing and assessing his or her personal performance in relation to established standards, and by revising or altering his or her practices and techniques appropriately.
- The ophthalmologist improves ophthalmic care by communicating to colleagues, through appropriate professional channels, knowledge gained through clinical research and practice. This includes alerting colleagues of instances of unusual or unexpected rates of complications and problems related to new drugs, devices or procedures.
- The ophthalmologist provides care in suitably staffed and equipped facilities adequate to deal with potential ocular and systemic complications requiring immediate attention.
- The ophthalmologist also provides ophthalmic care in a manner that is cost effective without unacceptably compromising accepted standards of quality.

Reviewed by: Council
Approved by: Board of Trustees
October 12, 1988

2nd Printing: January 1991
3rd Printing: August 2001
4th Printing: July 2005

APPENDIX 2. SUMMARY OF MAJOR RECOMMENDATIONS FOR CARE

DIAGNOSIS

History

- Duration of diabetes[1-3 [A:I]]
- Past glycemic control (hemoglobin A_{1c})[2-4 [A:I]]
- Medications[[A:III]]
- Medical history (e.g., obesity,[[A:III]] renal disease,[1,5 [A:II]] systemic hypertension,[1,5 [A:I]] serum lipid levels,[6 [A:II]] pregnancy[7,8 [A:I]])
- Ocular history[[A:III]] (e.g., trauma, ocular injections, surgery, including laser treatment and refractive surgery)

Examination

- Visual acuity[9 [A:I]]
- Slit-lamp biomicroscopy[[A:III]]
- Intraocular pressure[[A:III]]
- Gonioscopy when indicated[[A:III]]
- Dilated funduscopy including stereoscopic examination of the posterior pole[10 [A:I]]
- Examination of the peripheral retina and vitreous[[A:III]]

A dilated pupil is necessary to ensure optimal examination of the retina, because only 50% of eyes are correctly classified for the presence and severity of retinopathy through undilated pupils.[11 [A:I]] Slit-lamp biomicroscopy with accessory lenses is the recommended method to evaluate retinopathy in the posterior pole and midperipheral retina.[10 [A:III]] The examination of the peripheral retina is best performed with indirect ophthalmoscopy or with slit-lamp biomicroscopy, combined with a contact lens.[[A:III]]

Examination Schedule

TABLE A2-1 RECOMMENDED EYE EXAMINATION SCHEDULE FOR PATIENTS WITH DIABETES MELLITUS

Diabetes Type	Recommended Time of First Examination	Recommended Follow-up*
Type 1	3-5 years after diagnosis[1 [A:II]]	Yearly[1 [A:II]]
Type 2	At time of diagnosis[5,12 [A:II]]	Yearly[5,12 [A:II]]
Prior to pregnancy (type 1 or type 2)	Prior to conception and early in the first trimester[7,8,13 [A:I]]	No retinopathy to mild or moderate NPDR: every 3–12 months[7,8,13 [A:I]] Severe NPDR or worse: every 1–3 months[7,8,13 [A:I]]

NPDR = nonproliferative diabetic retinopathy

* Abnormal findings may dictate more frequent follow-up examinations.

TREATMENT

Laser photocoagulation surgery is the standard technique for treating diabetic retinopathy. In general, it is advised for patients with high-risk proliferative diabetic retinopathy, clinically significant macular edema, or neovascularization of the anterior chamber angle.[14-16 [A:I]] Detailed management recommendations for patients with diabetes are summarized in Table 6 and described in the main body of the text.

FOLLOW-UP

History

- Symptoms[A:III]
- Systemic status (pregnancy, blood pressure, serum cholesterol, renal status)[A:III]
- Glycemic status (hemoglobin A_{1c})[2-4 [A:I]]

Examination

- Visual acuity[9 [A:I]]
- Slit-lamp biomicroscopy with iris examination[17 [A:II]]
- Intraocular pressure[A:III]
- Gonioscopy (if iris neovascularization is suspected or present or if intraocular pressure is increased)[17 [A:II]]
- Stereoscopic examination of the posterior pole after dilation of the pupils[10 [A:I]]
- Peripheral retina and vitreous examination, when indicated[18 [A:II]]

Recommended intervals for follow-up are given in Table 6.

PROVIDER

Because of the complexities of the diagnosis and surgery for proliferative diabetic retinopathy, the ophthalmologist caring for patients with this condition should be familiar with the specific recommendations of the Diabetic Retinopathy Study, the Early Treatment Diabetic Retinopathy Study, the United Kingdom Prospective Diabetes Study, the Diabetes Control and Complications Trial, and the Epidemiology of Diabetes Interventions and Complications.[A:III] The ophthalmologist should also have training in and experience with the management of this particular condition.[A:III]

COUNSELING/REFERRAL

The ophthalmologist should refer patients with diabetes who do not have a primary care physician for appropriate management of their systemic condition.[A:III] The ophthalmologist should communicate examination results to the physician who is managing ongoing diabetes care.[A:III]

Those whose conditions fail to respond to surgery and those for whom further treatment is unavailable should be provided with proper professional support and offered referral for counseling, vision rehabilitation, or social services as appropriate.[19 [A:III]] Vision rehabilitation restores functional ability[20 [A:I]] and patients with functionally limiting postoperative visual impairment should be referred for vision rehabilitation and social services.[19 [A:III]] More information on vision rehabilitation, including materials for patients, is available at www.aao.org/smartsight.

REFERENCES

1. Klein R, Klein BE, Moss SE, et al. The Wisconsin Epidemiologic Study of Diabetic Retinopathy. II. Prevalence and risk of diabetic retinopathy when age at diagnosis is less than 30 years. Arch Ophthalmol 1984;102:520-6.
2. Klein R, Klein BE, Moss SE, et al. Glycosylated hemoglobin predicts the incidence and progression of diabetic retinopathy. JAMA 1988;260:2864-71.
3. Davis MD, Fisher MR, Gangnon RE, et al. Risk factors for high-risk proliferative diabetic retinopathy and severe visual loss: Early Treatment Diabetic Retinopathy Study report number 18. Invest Ophthalmol Vis Sci 1998;39:233-52.
4. Diabetes Control and Complications Trial Research Group. The effect of intensive diabetes treatment on the progression of diabetic retinopathy in insulin-dependent diabetes mellitus. The Diabetes Control and Complications Trial. Arch Ophthalmol 1995;113:36-51.
5. Klein R, Klein BE, Moss SE, et al. The Wisconsin Epidemiologic Study of Diabetic Retinopathy. III. Prevalence and risk of diabetic retinopathy when age at diagnosis is 30 or more years. Arch Ophthalmol 1984;102:527-32.

6. Chew EY, Klein ML, Ferris FL III, et al. Association of elevated serum lipid levels with retinal hard exudate in diabetic retinopathy. Early Treatment Diabetic Retinopathy Study (ETDRS) report 22. Arch Ophthalmol 1996;114:1079-84.
7. Klein BE, Moss SE, Klein R. Effect of pregnancy on progression of diabetic retinopathy. Diabetes Care 1990;13:34-40.
8. Chew EY, Mills JL, Metzger BE, et al. Metabolic control and progression of retinopathy. The Diabetes in Early Pregnancy Study. National Institute of Child Health and Human Development Diabetes in Early Pregnancy Study. Diabetes Care 1995;18:631-7.
9. Early Treatment Diabetic Retinopathy Study Research Group. Early photocoagulation for diabetic retinopathy. ETDRS report number 9. Ophthalmology 1991;98:766-85.
10. Early Treatment Diabetic Retinopathy Study Research Group. Photocoagulation for diabetic macular edema. Early Treatment Diabetic Retinopathy Study report number 1. Arch Ophthalmol 1985;103:1796-806.
11. Klein R, Klein BE, Neider MW, et al. Diabetic retinopathy as detected using ophthalmoscopy, a nonmydriatic camera and a standard fundus camera. Ophthalmology 1985;92:485-91.
12. The prevalence of retinopathy in impaired glucose tolerance and recent-onset diabetes in the Diabetes Prevention Program. Diabet Med 2007;24:137-44.
13. Diabetes Control and Complications Trial Research Group. Effect of pregnancy on microvascular complications in the diabetes control and complications trial. Diabetes Care 2000;23:1084-91.
14. Murphy RP, Egbert PR. Regression of iris neovascularization following panretinal photocoagulation. Arch Ophthalmol 1979;97:700-2.
15. Diabetic Retinopathy Study Research Group. Indications for photocoagulation treatment of diabetic retinopathy: Diabetic Retinopathy Study report number 14. Int Ophthalmol Clin 1987;27:239-53.
16. Early Treatment Diabetic Retinopathy Study Research Group. Treatment techniques and clinical guidelines for photocoagulation of diabetic macular edema. Early Treatment Diabetic Retinopathy Study report number 2. Ophthalmology 1987;94:761-74.
17. Jacobson DR, Murphy RP, Rosenthal AR. The treatment of angle neovascularization with panretinal photocoagulation. Ophthalmology 1979;86:1270-7.
18. Early Treatment Diabetic Retinopathy Study Research Group. Fundus photographic risk factors for progression of diabetic retinopathy. ETDRS report number 12. Ophthalmology 1991;98:823-33.
19. American Academy of Ophthalmology Vision Rehabilitation Committee. Preferred Practice Pattern® Guidelines. Vision Rehabilitation for Adults. San Francisco, CA: American Academy of Ophthalmology; 2012. Available at: www.aao.org/ppp.
20. Stelmack JA, Tang XC, Reda DJ, et al, LOVIT Study Group. Outcomes of the Veterans Affairs Low Vision Intervention Trial (LOVIT). Arch Ophthalmol 2008;126:608-17.

APPENDIX 3. TREATMENT TRIAL RESULTS

DIABETIC RETINOPATHY STUDY (1972-1979)

The Diabetic Retinopathy Study (DRS) was designed to investigate the value of xenon arc and argon photocoagulation surgery for patients with severe NPDR and PDR.[40] The results are shown in Table A3-1.

TABLE A3-1 VISUAL OUTCOME FOR XENON ARC AND ARGON LASER PHOTOCOAGULATION FROM THE DIABETIC RETINOPATHY STUDY

Baseline Severity of Retinopathy	Duration of Follow-up (Years)	Control Patients (% with Severe Visual Loss)	Treated Patients (% with Severe Visual Loss)
Severe nonproliferative	2	3	3
	4	13	4
Mild proliferative	2	7	3
	4	21	7
High-risk proliferative	2	26	11
	4	44	20

NOTE: Severe visual loss was defined as worse than 5/200 visual acuity at two or more consecutive completed visits (scheduled at 4-month intervals).

EARLY TREATMENT DIABETIC RETINOPATHY STUDY (1985-1990)

The Early Treatment Diabetic Retinopathy Study (ETDRS) investigated the value of photocoagulation surgery for patients with NPDR or PDR without high-risk characteristics.[43,51] The results for eyes with macular edema are shown in Table A3-2. Visual loss was defined as at least doubling of the visual angle (e.g., 20/20 to 20/40, or 20/50 to 20/100).

TABLE A3-2 VISUAL OUTCOME FOR LASER PHOTOCOAGULATION TREATMENT FROM THE EARLY TREATMENT DIABETIC RETINOPATHY STUDY

Extent of Macular Edema	Duration of Follow-up (Years)	Control Patients (% with Visual Loss)	Treated Patients (% with Visual Loss)
CSME (center of macula not involved)	1	8	1
	2	16	6
	3	22	13
CSME (center of macula involved)	1	13	8
	2	24	9
	3	33	14

CSME = clinically significant macular edema

NOTE: Visual loss was defined as at least doubling of the visual angle.

In eyes with NPDR or non-high-risk PDR, early panretinal photocoagulation was compared with deferral of photocoagulation, and although there was a beneficial treatment effect, the outlook for maintaining vision was good in both groups. The 5-year rates of severe visual loss or vitrectomy ranged from 2% to 6% in eyes assigned to early photocoagulation and from 4% to 10% in eyes assigned to deferral. Early panretinal photocoagulation was associated with side effects (small decreases in visual acuity and visual field) in some eyes, and the ETDRS concluded that deferral of photocoagulation was preferable at least until retinopathy was approaching the high-risk stage. Eyes approaching that stage had a 50% risk of reaching it within 12 to 18 months. Eyes in this category

had very severe NPDR or non-high-risk PDR characterized by NVD less than 1/4 to 1/3 disc area and/or NVE, without vitreous or preretinal hemorrhage.

Recent additional analyses of visual outcome in ETDRS patients with severe NPDR to non-high-risk PDR suggest that the recommendation to consider panretinal photocoagulation before the development of high-risk PDR is particularly appropriate for patients with type 2 diabetes.[113] The risk of severe vision loss or vitrectomy was reduced by 50% in those who were treated early compared with those who deferred treatment until high-risk PDR developed.

For patients with type 1 diabetes, the timing of the panretinal photocoagulation will depend on the compliance with follow-up, status and response to treatment of the fellow eye, impending cataract surgery, and/or pregnancy status.

DIABETIC RETINOPATHY VITRECTOMY STUDY (1983-1987)

The Diabetic Retinopathy Vitrectomy Study (DRVS) investigated the role of vitrectomy in managing eyes with very severe PDR.[55-58] The benefit of early vitrectomy for severe vitreous hemorrhage (defined as hemorrhage obscuring the macula or major retinal vessels for three disc diameters from the macular center) was seen in type 1 patients, but no such advantage was found in type 2 patients, who did not benefit from earlier surgery. Early vitrectomy was beneficial among patients with visual acuity of 5/200 or worse and severe vitreous hemorrhage with reduced vision for at least 1 month and without previous treatment or complications such as retinal detachment or neovascularization of the iris. Overall, at 2 years after surgery, 25% of the early vitrectomy group and 15% of the deferral group had visual acuity of 20/40 or better. The advantage was most pronounced in patients with type 1 diabetes (36% vs. 12% for early vitrectomy vs. deferral of vitrectomy, respectively) and was not statistically significant for patients with type 2 diabetes.

The DRVS showed that early vitrectomy was beneficial for patients with visual acuity of 20/400 or better plus one of the following: (1) severe neovascularization and fibrous proliferation; (2) fibrous proliferation and moderate vitreous hemorrhage; or (3) moderate neovascularization, severe fibrous proliferation, and moderate vitreous hemorrhage. Among such patients, 44% with early vitrectomy and 28% in the observation group had visual acuity of 20/40 or better at 4 years of follow-up.

The results of the DRVS should be interpreted in light of subsequent advances in vitreoretinal surgery, such as the introduction of endoscopic and indirect ophthalmoscopic laser photocoagulation. The use of long-acting intraocular gases such as sulfur hexafluoride and perfluoropropane, the use of viscodissection, and the use of heavier-than-water liquids such as perfluoro-octane are advances in vitreoretinal surgery that developed after the DRVS. Thus, the results may actually be better than those reported in the DRVS.[146] Early vitrectomy should be considered for selected patients with type 2 diabetes, particularly those in whom severe vitreous hemorrhage prohibits laser therapy photocoagulation of active neovascularization.

APPENDIX 4. GLYCEMIC CONTROL

The Diabetes Control and Complications Trial (DCCT) was a multicenter, randomized controlled trial designed to study the connection between glycemic control and retinal, renal, and neurologic complications of type 1 diabetes mellitus. Published results from this trial demonstrated that improved blood sugar control can delay the onset and slow the progression of diabetic retinopathy, nephropathy, and neuropathy in type 1 patients.[37] The DCCT showed a strong exponential relationship between the risk of diabetic retinopathy and the mean hemoglobin A_{1c} level. For each 10% decrease in the hemoglobin A_{1c} (e.g., from 9.0% to 8.1%), there was a 39% decrease in the risk of progression of retinopathy over the range of hemoglobin A_{1c} values. There was no glycemic threshold at which the risk of retinopathy was eliminated above the nondiabetic range of hemoglobin A_{1c} (4.0% to 6.05%).

After 6.5 years of follow-up, the DCCT ended, and all patients were encouraged to pursue strict control of blood sugar. Most of these patients are being followed in the Epidemiology of Diabetes Interventions and Complications (EDIC) trial, which includes 95% of the DCCT subjects. A total of 1,294 to 1,335 patients have been examined annually in the EDIC study. Further progression of diabetic retinopathy during the first 4 years of the EDIC study was 66% to 77% less in the former intensive treatment group than in the former conventional treatment group.[21] The benefit persisted even at 7 years. This benefit included an effect on severe diabetic retinopathy, including severe NPDR, PDR, CSME, and the need for focal/grid or panretinal laser photocoagulation.[23] The decrease in hemoglobin A_{1c} from 9% to approximately 8% did not drastically reduce the progression of diabetic retinopathy in the former conventional treatment group, nor did the increase in hemoglobin A_{1c} from approximately 7% to approximately 8% drastically accelerate diabetic retinopathy in the former intensive treatment group.[21] Thus, it takes time for improvements in control to negate the long-lasting effects of prior prolonged hyperglycemia, and once the biological effects of prolonged improved control are manifest, the benefits are long-lasting. Furthermore, the total glycemic exposure of the patient (i.e., degree and duration) determines the degree of retinopathy observed at any one time.

A positive relationship between the 4-year incidence and progression of retinopathy and glycosylated hemoglobin remains after controlling for other risk factors, such as duration of diabetes and severity of retinopathy at a baseline examination.[33,34,92] Extrapolation of pathologic and clinical experience strongly suggests that poor levels of control contribute to microangiopathy, including retinopathy.[147] The development of PDR parallels an increased risk of nephropathy, myocardial infarction, and/or cerebral vascular accidents.

Although good glycemic control is advised, there is some evidence that rapid improvement of long-standing poor control may increase the risk of retinopathy progression over the first year for some patients. About 10% of type 1 diabetic patients who had initial retinopathy at the beginning of the DCCT had increased retinopathy progression.[148] Specifically, there may be a transient increase in the number of cotton-wool spots seen on retinal examination. Frequent ophthalmologic monitoring is important when patients are being brought under better control.[148]

In the DCCT there was a threefold increase in severe hypoglycemic events and excess weight gain among patients using intensive treatment regimens. Increased risk of hypoglycemia is a consequence of strict blood glucose control. Irregular food intake, failure to check blood glucose before planned or unplanned vigorous exercise or before operating a motor vehicle, and excess alcohol are risk factors for hypoglycemia. Diabetes mellitus education and regular reinforcement should be provided by diabetes nurses and dietitian educators and may help minimize the risk of hypoglycemia.

The United Kingdom Prospective Diabetes Study (UKPDS),[24,87] a randomized controlled clinical trial of blood glucose control, enrolled 3,867 patients with newly diagnosed type 2 diabetes. Intensive blood glucose control by either the sulfonylureas or insulin decreased the risk of microvascular complications but not the risk of macrovascular disease. There were no adverse effects of the individual drugs on the cardiovascular outcome. In this study, there was a 29% reduction in the need for retinal photocoagulation in the group that had intensive glucose therapy compared with those that had conventional treatment (relative risk, 0.71; 95% confidence interval, 0.53–0.96; P=0.003).

APPENDIX 5. CLASSIFICATION OF DIABETIC RETINOPATHY IN THE EARLY TREATMENT OF DIABETIC RETINOPATHY STUDY

The Early Treatment of Diabetic Retinopathy Study (ETDRS) classification of diabetic retinopathy and definitions of macular edema are in Tables A5-1 and A5-2.

TABLE A5-1 CLASSIFICATION OF DIABETIC RETINOPATHY IN THE EARLY TREATMENT OF DIABETIC RETINOPATHY STUDY

Disease Severity Level	Findings Observable upon Dilated Ophthalmoscopy
Mild nonproliferative retinopathy	At least one microaneurysm, and definition not met for moderate nonproliferative retinopathy, severe nonproliferative retinopathy, early proliferative retinopathy, or high-risk proliferative retinopathy (see below)
Moderate nonproliferative retinopathy	Hemorrhages and/or microaneurysms ≥ standard photograph 2A*; and/or soft exudates, venous beading, or intraretinal microvascular abnormalities definitely present; and definition not met for severe nonproliferative retinopathy, early proliferative retinopathy, or high-risk proliferative retinopathy (see below)
Severe nonproliferative retinopathy	Soft exudates, venous beading, and intraretinal microvascular abnormalities all definitely present in at least two of fields four through seven; or two of the preceding three lesions present in at least two of fields four through seven and hemorrhages and microaneurysms present in these four fields, equaling or exceeding standard photo 2A in at least one of them; or intraretinal microvascular abnormalities present in each of fields four through seven and equaling or exceeding standard photograph 8A in at least two of them; and definition not met for early proliferative retinopathy or high-risk proliferative retinopathy (see below)
Early proliferative retinopathy (i.e., proliferative retinopathy without Diabetic Retinopathy Study high-risk characteristics)	New vessels; and definition not met for high-risk proliferative retinopathy (see below)
High-risk proliferative retinopathy (proliferative retinopathy with Diabetic Retinopathy Study high-risk characteristics)	New vessels on or within one disc diameter of the optic disc (NVD) ≥ standard photograph 10A* (about one-quarter to one-third disc area), with or without vitreous or preretinal hemorrhage; or vitreous and/or preretinal hemorrhage accompanied by new vessels, either NVD < standard photograph 10A or new vessels elsewhere (NVE) ≥ one-quarter disc area

* Early Treatment Diabetic Retinopathy Study Research Group. Grading diabetic retinopathy from stereoscopic color fundus photographs--an extension of the modified Airlie House classification. ETDRS report number 10. Ophthalmology 1991;98:786-806.

Adapted from the Early Treatment Diabetic Retinopathy Study Research Group. Early Treatment Diabetic Retinopathy Study design and baseline patient characteristics. ETDRS report number 7. Ophthalmology 1991;98:742.

TABLE A5-2 DIABETIC MACULAR EDEMA DISEASE DEFINITIONS IN THE EARLY TREATMENT OF DIABETIC RETINOPATHY STUDY

Disease Severity Level	Findings Observable upon Dilated Ophthalmoscopy
Diabetic macular edema apparently absent	No apparent retinal thickening or hard exudates in posterior pole
Diabetic macular edema apparently present	Thickening of retina within one disc diameter of the center of the macula; and/or hard exudates ≥ standard photograph 3* in a standard 30º photographic field centered on the macula (field 2), with some hard exudates within one disc diameter of the center of the macula
Clinically significant macular edema	Retinal thickening at or within 500 μm of the center of the macula; and/or hard exudates at or within 500 μm of the center of the macula, if associated with thickening of the adjacent retina; and/or a zone or zones of retinal thickening one disc area in size at least part of which was within one disc diameter of the center

* Early Treatment Diabetic Retinopathy Study Research Group. Grading diabetic retinopathy from stereoscopic color fundus photographs--an extension of the modified Airlie House classification. ETDRS report number 10. Ophthalmology 1991;98:786-806.

Adapted from the Early Treatment Diabetic Retinopathy Study Research Group. Early Treatment Diabetic Retinopathy Study design and baseline patient characteristics. ETDRS report number 7. Ophthalmology 1991;98:742.

APPENDIX 6. COST-BENEFIT ANALYSES

Methods to evaluate whether the cost of a health care intervention is a good use of available resources include cost-effectiveness or cost-utility calculations. While cost-effectiveness analyses use monetary terms, cost-utility analyses include the value that a patient places on the quality of additional years of life, using a measure called the quality-adjusted life year (QALY). The QALY is a generic outcome measure of the improvement in quality and quantity of life after a health care intervention and so enables comparison of the value of interventions for different health conditions.[149,150] In calculating the QALY, researchers use the economic technique of discounting to reflect the time-value of money because the effect gained from the dollars spent on the treatment remains over the course of the lifetime of the patient.[151,152] The lower the amount calculated for a QALY, the better the value of the intervention. A further refinement incorporates other parameters to describe value-based medicine analyses.[153]

Computer-simulation models have been designed to predict the medical and economic effects of applying accepted methods for controlling diabetic retinopathy among patients with type 1 diabetes.[154-156] In one study, recommendations for screening were taken from the Public Health Committee of the American Academy of Ophthalmology. Surgery recommendations and modeled treatment efficacy were drawn from the reports of the Diabetic Retinopathy Study (DRS) and the Early Treatment Diabetic Retinopathy Study (ETDRS). Costs of screening and surgery were drawn from published Medicare reimbursement data.

The model predicted that over their lifetime, 72% of patients with type 1 diabetes will eventually develop PDR requiring panretinal photocoagulation and that 42% will develop macular edema.[154] If treatments are delivered as recommended in the clinical trials, the model predicted a cost of $966 per person-year of vision saved from PDR and $1,120 per person-year of central visual acuity saved from macular edema. These costs are less than the cost of a year of Social Security disability payments for those disabled by vision loss. In addition, if all patients with type 1 diabetes received eye care at federal expense, the predicted savings exceed $167.0 million and 79,236 person-years of sight.[156] Therefore, treatment yields a substantial savings compared with the direct cost to society of the case of an untreated type 1 patient. The indirect costs in lost productivity and human suffering are even greater.

Another analysis, using the same computer model, predicted the cost-effectiveness of detecting and treating diabetic retinopathy from the insurers' perspective.[157] Screening and treatment of eye disease in patients with diabetes costs, on average, $3,190 per QALY saved. For patients with type 1 diabetes, it costs $1,996 per QALY saved; for patients with type 2 diabetes who use insulin, it costs $2,933 per QALY saved; and for patients with type 2 diabetes who do not use insulin, it costs $3,530 per QALY saved. The cost savings are weighted based on the prevalence of the disease; thus, the savings are greatest when screening is performed for those with type 2 diabetes not using insulin, the largest subgroup of this population with diabetes.

For comparison, the cost-utility of laser photocoagulation for diabetic macular edema is $3,101/QALY[158] and laser photocoagulation for extrafoveal choroidal neovascularization is $23,640/QALY.[159] For comparisons outside of ophthalmology, the cost-utility in other areas of medicine have been calculated as follows: single-vessel coronary artery bypass surgery for disease of the left anterior descending artery costs $7,000/QALY; treatment of systemic arterial hypertension (diastolic 95-103 mmHg in males aged 40) costs $58,000/QALY; and ambulatory peritoneal dialysis costs $90,000/QALY.[158]

A United Kingdom study compared the cost-effectiveness of conventional versus intensive blood-glucose control in patients with type 2; it found that intensive management increased treatment costs but substantially reduced the costs of complications related to diabetes and increased the time free of complications. Although costs were reduced for the treatment of diabetic retinopathy in the intensive management group, these findings were not statistically significant.[160]

A cost-utility analysis using a computer model of detection and treatment of diabetic retinopathy in patients with type 1 and type 2 diabetes demonstrated that ophthalmic care reduced the prevalence of blindness by 52% and that the direct costs of care were less than the losses in productivity and the costs of facilities provided for disability.[161]

GLOSSARY

Clinically significant macular edema (CSME): Retinal thickening at or within 500 microns of the center of the macula; and/or hard exudates at or within 500 microns of the center of the macula, if associated with thickening of the adjacent retina; and/or a zone or zones of retinal thickening one disc area in size, any part of which is within 1 disc diameter of the center of the macula.

CSME: See Clinically significant macular edema.

DCCT: See Diabetes Control and Complications Trial.

Diabetes Control and Complications Trial (DCCT): A multicenter, randomized controlled trial designed to study the connection between glycemic control and retinal, renal, and neurologic complications of type 1 diabetes mellitus. (See Appendix 4.)

Diabetes mellitus: According to the American Diabetes Association Expert Committee on the Diagnosis and Classification of Diabetes Mellitus, the criteria for the diagnosis of diabetes mellitus are as follows.
Fasting plasma glucose equal to or exceeding 126 mg/dL (7.0 mmol/L). Fasting is defined as no caloric intake for at least 8 hours.

or

Symptoms of hyperglycemia and a casual plasma glucose concentration equal to or exceeding 200 mg/dL (11.1 mmol/L). “Casual” is defined as any time of day without regard to time since last meal. The classic symptoms of hyperglycemia include polyuria, polydipsia, and unexplained weight loss.

or

A plasma glucose measurement at 2 hours postload equal to or exceeding 200 mg/dL (11.1 mmol/L) during an oral glucose tolerance test. The test is be performed as described by the World Health Organization, using a glucose load containing the equivalent of 75 g anhydrous glucose dissolved in water. However, the expert committee has recommended against oral glucose tolerance testing for routine clinical use. (Source: Report of the Expert Committee on the Diagnosis and Classification of Diabetes Mellitus. Diabetes Care 2008; 31 (suppl):55-60.)

Diabetes type: Type 1, previously called juvenile-onset or insulin-dependent diabetes, is characterized by beta-cell destruction and usually leads to absolute insulin deficiency. Type 2, previously called adult-onset or noninsulin-dependent diabetes, ranges from predominantly insulin resistance with relative insulin deficiency to predominantly an insulin secretory defect with insulin resistance. (Source: Report of the Expert Committee on the Diagnosis and Classification of Diabetes Mellitus. Diabetes Care 2008; 31 (suppl):55-60.)

Diabetic Retinopathy Study (DRS): A study designed to investigate the value of xenon arc and argon photocoagulation surgery for patients with severe NPDR and PDR. (See Appendix 3.)

Diabetic Retinopathy Vitrectomy Study (DRVS): A study that investigated the role of vitrectomy in managing eyes with very severe PDR. (See Appendix 3.)

DRS: See Diabetic Retinopathy Study.

DRVS: See Diabetic Retinopathy Vitrectomy Study.

Early Treatment Diabetic Retinopathy Study (ETDRS): A study that investigated the value of photocoagulation surgery for patients with NPDR or PDR without high-risk characteristics. (See Appendix 3.)

Early proliferative diabetic retinopathy (i.e., proliferative retinopathy without DRS high-risk characteristics)**:** New vessels that do not meet the criteria of high-risk proliferative retinopathy.

EDIC: See Epidemiology of Diabetes Interventions and Complications study.

Epidemiology of Diabetes Interventions and Complications study (EDIC): An observational study following 95% of the DCCT subjects. (See Appendix 4.)

ETDRS: See Early Treatment Diabetic Retinopathy Study.

Focal photocoagulation: A laser technique directed to abnormal blood vessels with specific areas of focal leakage (i.e., microaneurysms) to reduce chronic fluid leakage in patients with macular edema.

Grid photocoagulation: A laser technique in which a grid pattern of scatter burns is applied in areas of diffuse macular edema and nonperfusion. Typically, fluorescein angiograms of these areas show a diffuse pattern rather than focal leakage.

High-risk proliferative diabetic retinopathy (PDR): New vessels on or within one disc diameter of the optic disc equaling or exceeding standard photograph 10A (about one-quarter to one-third disc area), with or without vitreous or preretinal hemorrhage; or vitreous and/or preretinal hemorrhage accompanied by new vessels either on the optic disc less than standard photograph 10A or new vessels elsewhere equaling or exceeding one-quarter disc area.

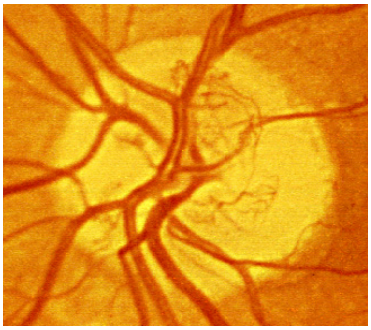

Standard photograph 10A defines the lower border of moderate NVD. NVD covers approximately one-third the area of the standard disc. This extent of NVD alone would constitute PDR with high-risk characteristics.

Reprinted with permission from the Early Treatment Diabetic Retinopathy Study Research Group. Grading diabetic retinopathy from stereoscopic color fundus photographs--an extension of the modified Airlie House classification. ETDRS report number 10. Ophthalmology 1991;98:786-806.

ICD-9: International Statistical Classification of Diseases and Related Health Problems, Ninth Edition.

Intraretinal microvascular abnormalities (IRMA): Tortuous intraretinal vascular segments, varying in caliber from barely visible to 31 microns in diameter (one-quarter the width of a major vein at the disc margin); they occasionally can be larger. IRMA may be difficult to distinguish from neovascularization.

IRMA: See Intraretinal microvascular abnormalities.

Macular edema: Thickening of the retina within one or two disc diameters of the center of the macula.

Mild nonproliferative diabetic retinopathy (NPDR): At least one microaneurysm and less than moderate nonproliferative diabetic retinopathy.

Moderate nonproliferative diabetic retinopathy (NPDR): Hemorrhages and/or microaneurysms greater than standard photograph 2A, and/or soft exudates, venous beading, or intraretinal microvascular abnormalities present but less than severe nonproliferative retinopathy.

Moderate visual loss: The loss of 15 or more letters on the ETDRS visual acuity chart, or doubling of the visual angle (e.g., 20/20 to 20/40, or 20/50 to 20/100).

New vessels at the optic disc (NVD): New vessels at the optic disc; neovascularization on or within one disc diameter of the optic disc.

New vessels elsewhere in the retina (NVE): New vessels elsewhere in the retina; neovascularization elsewhere in the retina and greater than one disc diameter from the optic disc margin.

New vessels on the iris (NVI): New vessels on the iris; neovascularization of the iris.

Nonproliferative diabetic retinopathy (NPDR): The phases of diabetic retinopathy with no evidence of retinal neovascularization.

NPDR: See Nonproliferative diabetic retinopathy.

NVD: See New vessels at the optic disc.

NVE: See New vessels elsewhere in the retina.

NVI: See New vessels on the iris.

Panretinal photocoagulation (PRP): A type of laser surgery used for patients with proliferative diabetic retinopathy. The surgery is delivered in a scatter pattern throughout the peripheral fundus and is intended to lead to a regression of neovascularization.

PDR: See Proliferative diabetic retinopathy.

Proliferative diabetic retinopathy (PDR): Advanced disease characterized by NVD and/or NVE.

PRP: See Panretinal photocoagulation.

Retinal hard exudate: Protein and lipid accumulation within the retina.

Scatter photocoagulation: See Panretinal photocoagulation (PRP).

Severe nonproliferative diabetic retinopathy (NPDR): Using the 4-2-1 rule, the presence of at least one of the following features: (1) severe intraretinal hemorrhages and microaneurysms, equaling or exceeding standard photograph 2A, present in four quadrants; (2) venous beading in two or more quadrants (standard photograph 6A); or (3) moderate intraretinal microvascular abnormalities equaling or exceeding standard photograph 8A in one or more quadrants.

Severe visual loss: Occurrence of visual acuity worse than 5/200 at any two consecutive visits scheduled at 4-month intervals.

UKPDS: See United Kingdom Prospective Diabetes Study.

United Kingdom Prospective Diabetes Study (UKPDS): A randomized controlled clinical trial of blood glucose control in patients with newly diagnosed type 2 diabetes. (See Appendix 4.)

Standard photograph 2A, the standard for hemorrhages/microaneurysms. Eyes with severe NPDR have this degree of severity of hemorrhages and microaneurysms in all four midperipheral quadrants.

Standard photograph 6A, less severe of two standards for venous beading. Two main branches of the superior temporal vein show beading that is definite, but not severe.

Standard photograph 8A, the standard for moderate IRMA. Patients with severe NPDR have moderate IRMA of at least this severity in at least one quadrant.

Reprinted with permission from the Early Treatment Diabetic Retinopathy Study Research Group. Grading diabetic retinopathy from stereoscopic color fundus photographs--an extension of the modified Airlie House classification. ETDRS report number 10. Ophthalmology 1991;98:786-806.

RELATED ACADEMY MATERIALS

Basic and Clinical Science Course

Retina and Vitreous (Section 12, 2012-2013)

Focal Points

Intensive Therapies in Managing Diabetes Mellitus (2009)

Intravitreal Injections (2009)

Optical Coherence Tomography in the Management of Retinal Disorders (2006)

Update on the Management of Diabetic Retinopathy (2011)

Clinical Skills DVD

Diagnostic Imaging of Retinal Disease (2012)

Ophthalmic Technology Assessment

Anti-VEGF Pharmacotherapy for Diabetic Macular Edema (2012)

Laser Scanning Imaging for Macular Disease (2007)

Single Field Fundus Photography for Diabetic Retinopathy Screening (2004; Reviewed for currency 2010)

Patient Education

Diabetic Retinopathy Brochure (Spanish: Retinopatía Diabetíca)

EyeSmart® What is Diabetic Retinopathy? Available at: http://www.geteyesmart.org/eyesmart/diseases/diabetic-retinopathy.cfm

ojosSanos™ ¿Qué Es la Retinopatía Diabética? Disponible en http://www.geteyesmart.org/eyesmart/diseases-es/retinopatia-diabetica.cfm

Understanding Diabetic Retinopathy DVD (includes English and Spanish) (2008)

Preferred Practice Pattern

Comprehensive Adult Medical Eye Evaluation (2010)

To order any of these materials, please call the Academy's Customer Service number, 866.561.8558 (US only) or 415.561.8540 or visit www.aao.org/store.

REFERENCES

1. Expert Committee on the Diagnosis and Classification of Diabetes Mellitus. Report of the Expert Committee on the Diagnosis and Classification of Diabetes Mellitus. Diabetes Care 2003;26 Suppl 1:S5-20.
2. Klein R, Klein BE, Moss SE. Visual impairment in diabetes. Ophthalmology 1984;91:1-9.
3. Eppens MC, Craig ME, Cusumano J, et al. Prevalence of diabetes complications in adolescents with type 2 compared with type 1 diabetes. Diabetes Care 2006;29:1300-6.
4. Cowie CC, Rust KF, Byrd-Holt DD, et al. Prevalence of diabetes and impaired fasting glucose in adults in the U.S. population: National Health And Nutrition Examination Survey 1999-2002. Diabetes Care 2006;29:1263-8.
5. American Association of Clinical Endocrinologists. State of Diabetes Complications in America. Available at: www.aace.com/newsroom/press/2007/images/DiabetesComplicationsReport_FINAL.pdf. Accessed May 7, 2008.
6. Acton KJ, Burrows NR, Moore K, et al. Trends in diabetes prevalence among American Indian and Alaska native children, adolescents, and young adults. Am J Public Health 2002;92:1485-90.
7. Prevalence of diagnosed diabetes among American Indians/Alaskan Natives--United States, 1996. MMWR Morb Mortal Wkly Rep 1998;47:901-4.
8. Pinhas-Hamiel O, Zeitler P. The global spread of type 2 diabetes mellitus in children and adolescents. J Pediatr 2005;146:693-700.
9. Urakami T, Kubota S, Nitadori Y, et al. Annual incidence and clinical characteristics of type 2 diabetes in children as detected by urine glucose screening in the Tokyo metropolitan area. Diabetes Care 2005;28:1876-81.
10. Wei JN, Sung FC, Lin CC, et al. National surveillance for type 2 diabetes mellitus in Taiwanese children. JAMA 2003;290:1345-50.
11. Fagot-Campagna A, Pettitt DJ, Engelgau MM, et al. Type 2 diabetes among North American children and adolescents: an epidemiologic review and a public health perspective. J Pediatr 2000;136:664-72.
12. McMahon SK, Haynes A, Ratnam N, et al. Increase in type 2 diabetes in children and adolescents in Western Australia. Med J Aust 2004;180:459-61.
13. Kaufman FR. Type 2 diabetes mellitus in children and youth: a new epidemic. J Pediatr Endocrinol Metab 2002;15 Suppl 2:737-44.
14. Kempen JH, O'Colmain BJ, Leske MC, et al. The prevalence of diabetic retinopathy among adults in the United States. Arch Ophthalmol 2004;122:552-63.
15. Klein R, Klein BE, Moss SE, et al. The Wisconsin Epidemiologic Study of Diabetic Retinopathy. II. Prevalence and risk of diabetic retinopathy when age at diagnosis is less than 30 years. Arch Ophthalmol 1984;102:520-6.
16. Varma R, Torres M, Pena F, et al. Prevalence of diabetic retinopathy in adult Latinos: the Los Angeles Latino eye study. Ophthalmology 2004;111:1298-306.
17. Hirai FE, Knudtson MD, Klein BE, Klein R. Clinically significant macular edema and survival in type 1 and type 2 diabetes. Am J Ophthalmol 2008;145:700-6.
18. West SK, Klein R, Rodriguez J, et al. Diabetes and diabetic retinopathy in a Mexican-American population: Proyecto VER. Diabetes Care 2001;24:1204-9.
19. Klein R, Klein BE, Moss SE, et al. The Wisconsin Epidemiologic Study of Diabetic Retinopathy. III. Prevalence and risk of diabetic retinopathy when age at diagnosis is 30 or more years. Arch Ophthalmol 1984;102:527-32.
20. Diabetes Control and Complications Trial Research Group. Progression of retinopathy with intensive versus conventional treatment in the Diabetes Control and Complications Trial. Ophthalmology 1995;102:647-61.
21. Diabetes Control and Complications Trial/Epidemiology of Diabetes Interventions and Complications Research Group. Retinopathy and nephropathy in patients with type 1 diabetes four years after a trial of intensive therapy. N Engl J Med 2000;342:381-9.

22. Diabetes Control and Complications Trial Research Group. The relationship of glycemic exposure (HbA1c) to the risk of development and progression of retinopathy in the Diabetes Control and Complications Trial. Diabetes 1995;44:968-83.
23. Writing Team for the Diabetes Control and Complications Trial/Epidemiology of Diabetes Interventions and Complications Research Group. Effect of intensive therapy on the microvascular complications of type 1 diabetes mellitus. JAMA 2002;287:2563-9.
24. UK Prospective Diabetes Study (UKPDS) Group. Intensive blood-glucose control with sulphonylureas or insulin compared with conventional treatment and risk of complications in patients with type 2 diabetes (UKPDS 33). Lancet 1998;352:837-53.
25. Kohner EM, Stratton IM, Aldington SJ, et al. Relationship between the severity of retinopathy and progression to photocoagulation in patients with Type 2 diabetes mellitus in the UKPDS (UKPDS 52). Diabet Med 2001;18:178-84.
26. Wong TY, Liew G, Tapp RJ, et al. Relation between fasting glucose and retinopathy for diagnosis of diabetes: three population-based cross-sectional studies. Lancet 2008;371:736-43.
27. Davis MD, Fisher MR, Gangnon RE, et al. Risk factors for high-risk proliferative diabetic retinopathy and severe visual loss: Early Treatment Diabetic Retinopathy Study report number 18. Invest Ophthalmol Vis Sci 1998;39:233-52.
28. UK Prospective Diabetes Study Group. Tight blood pressure control and risk of macrovascular and microvascular complications in type 2 diabetes: UKPDS 38. BMJ 1998;317:703-13.
29. Snow V, Weiss KB, Mottur-Pilson C. The evidence base for tight blood pressure control in the management of type 2 diabetes mellitus. Ann Intern Med 2003;138:587-92.
30. van Leiden HA, Dekker JM, Moll AC, et al. Blood pressure, lipids, and obesity are associated with retinopathy: The Hoorn Study. Diabetes Care 2002;25:1320-5.
31. Klein R, Sharrett AR, Klein BE, et al. The association of atherosclerosis, vascular risk factors, and retinopathy in adults with diabetes: the atherosclerosis risk in communities study. Ophthalmology 2002;109:1225-34.
32. Lyons TJ, Jenkins AJ, Zheng D, et al. Diabetic retinopathy and serum lipoprotein subclasses in the DCCT/EDIC cohort. Invest Ophthalmol Vis Sci 2004;45:910-8.
33. Klein R, Klein BE, Moss SE, et al. The Wisconsin Epidemiologic Study of Diabetic Retinopathy. IX. Four-year incidence and progression of diabetic retinopathy when age at diagnosis is less than 30 years. Arch Ophthalmol 1989;107:237-43.
34. Klein R, Klein BE, Moss SE, et al. The Wisconsin Epidemiologic Study of Diabetic Retinopathy. X. Four-year incidence and progression of diabetic retinopathy when age at diagnosis is 30 years or more. Arch Ophthalmol 1989;107:244-9.
35. Kriska AM, LaPorte RE, Patrick SL, et al. The association of physical activity and diabetic complications in individuals with insulin-dependent diabetes mellitus: the Epidemiology of Diabetes Complications Study--VII. J Clin Epidemiol 1991;44:1207-14.
36. American Diabetes Association. Standards of medical care in diabetes--2008. Diabetes Care 2008;31 Suppl 1:S12-54.
37. Diabetes Control and Complications Trial Research Group. The effect of intensive treatment of diabetes on the development and progression of long-term complications in insulin-dependent diabetes mellitus. N Engl J Med 1993;329:977-86.
38. Diabetes Control and Complications Trial Research Group. The effect of intensive diabetes treatment on the progression of diabetic retinopathy in insulin-dependent diabetes mellitus. The Diabetes Control and Complications Trial. Arch Ophthalmol 1995;113:36-51.
39. Epidemiology of Diabetes Interventions and Complications (EDIC). Design, implementation, and preliminary results of a long-term follow-up of the Diabetes Control and Complications Trial cohort. Diabetes Care 1999;22:99-111.
40. Diabetic Retinopathy Study Research Group. Indications for photocoagulation treatment of diabetic retinopathy: Diabetic Retinopathy Study report number 14. Int Ophthalmol Clin 1987;27:239-53.
41. Diabetic Retinopathy Study Research Group. Photocoagulation treatment of proliferative diabetic retinopathy: the second report of Diabetic Retinopathy Study findings. Ophthalmology 1978;85:82-106.

42. Diabetic Retinopathy Study Research Group. Four risk factors for severe visual loss in diabetic retinopathy. The third report from the Diabetic Retinopathy Study. Arch Ophthalmol 1979;97:654-5.
43. Early Treatment Diabetic Retinopathy Study Research Group. Early photocoagulation for diabetic retinopathy. ETDRS report number 9. Ophthalmology 1991;98:766-85.
44. Early Treatment Diabetic Retinopathy Study Research Group. Early Treatment Diabetic Retinopathy Study design and baseline patient characteristics. ETDRS report number 7. Ophthalmology 1991;98:741-56.
45. Early Treatment Diabetic Retinopathy Study Research Group. Effects of aspirin treatment on diabetic retinopathy. ETDRS report number 8. Ophthalmology 1991;98:757-65.
46. Early Treatment Diabetic Retinopathy Study Research Group. Grading diabetic retinopathy from stereoscopic color fundus photographs--an extension of the modified Airlie House classification. ETDRS report number 10. Ophthalmology 1991;98:786-806.
47. Early Treatment Diabetic Retinopathy Study Research Group. Classification of diabetic retinopathy from fluorescein angiograms. ETDRS report number 11. Ophthalmology 1991;98:807-22.
48. Early Treatment Diabetic Retinopathy Study Research Group. Fundus photographic risk factors for progression of diabetic retinopathy. ETDRS report number 12. Ophthalmology 1991;98:823-33.
49. Early Treatment Diabetic Retinopathy Study Research Group. Fluorescein angiographic risk factors for progression of diabetic retinopathy. ETDRS report number 13. Ophthalmology 1991;98:834-40.
50. ETDRS Investigators. Aspirin effects on mortality and morbidity in patients with diabetes mellitus. Early Treatment Diabetic Retinopathy Study report 14. JAMA 1992;268:1292-300.
51. Early Treatment Diabetic Retinopathy Study Research Group. Photocoagulation for diabetic macular edema. Early Treatment Diabetic Retinopathy Study report number 1. Arch Ophthalmol 1985;103:1796-806.
52. Early Treatment Diabetic Retinopathy Study Research Group. Treatment techniques and clinical guidelines for photocoagulation of diabetic macular edema. Early Treatment Diabetic Retinopathy Study report number 2. Ophthalmology 1987;94:761-74.
53. Early Treatment Diabetic Retinopathy Study Research Group. Techniques for scatter and local photocoagulation treatment of diabetic retinopathy: Early Treatment Diabetic Retinopathy Study report number 3. Int Ophthalmol Clin 1987;27:254-64.
54. Early Treatment Diabetic Retinopathy Study Research Group. Focal photocoagulation treatment of diabetic macular edema. Relationship of treatment effect to fluorescein angiographic and other retinal characteristics at baseline: ETDRS report number 19. Arch Ophthalmol 1995;113:1144-55.
55. Diabetic Retinopathy Vitrectomy Study Research Group. Early vitrectomy for severe vitreous hemorrhage in diabetic retinopathy. Two-year results of a randomized trial. Diabetic Retinopathy Vitrectomy Study report 2. Arch Ophthalmol 1985;103:1644-52.
56. Diabetic Retinopathy Vitrectomy Study Research Group. Early vitrectomy for severe proliferative diabetic retinopathy in eyes with useful vision. Results of a randomized trial--Diabetic Retinopathy Vitrectomy Study report 3. Ophthalmology 1988;95:1307-20.
57. Diabetic Retinopathy Vitrectomy Study Research Group. Early vitrectomy for severe proliferative diabetic retinopathy in eyes with useful vision. Clinical application of results of a randomized trial--Diabetic Retinopathy Vitrectomy Study report 4. Ophthalmology 1988;95:1321-34.
58. Diabetic Retinopathy Vitrectomy Study Research Group. Early vitrectomy for severe vitreous hemorrhage in diabetic retinopathy. Four-year results of a randomized trial: Diabetic Retinopathy Vitrectomy Study report 5. Arch Ophthalmol 1990;108:958-64.
59. UK Prospective Diabetes Study (UKPDS) Group. Effect of intensive blood-glucose control with metformin on complications in overweight patients with type 2 diabetes (UKPDS 34). Lancet 1998;352:854-65.
60. Wilkinson CP, Ferris FL III, Klein RE, et al. Proposed international clinical diabetic retinopathy and diabetic macular edema disease severity scales. Ophthalmology 2003;110:1677-82.
61. Tuomilehto J, Lindstrom J, Eriksson JG, et al. Prevention of type 2 diabetes mellitus by changes in lifestyle among subjects with impaired glucose tolerance. N Engl J Med 2001;344:1343-50.
62. Knowler WC, Barrett-Connor E, Fowler SE, et al. Reduction in the incidence of type 2 diabetes with lifestyle intervention or metformin. N Engl J Med 2002;346:393-403.
63. Ferris FL, III. How effective are treatments for diabetic retinopathy? JAMA 1993;269:1290-1.

64. Kraft SK, Marrero DG, Lazaridis EN, et al. Primary care physicians' practice patterns and diabetic retinopathy. Current levels of care. Arch Fam Med 1997;6:29-37.
65. Schoenfeld ER, Greene JM, Wu SY, Leske MC. Patterns of adherence to diabetes vision care guidelines: baseline findings from the Diabetic Retinopathy Awareness Program. Ophthalmology 2001;108:563-71.
66. Paz SH, Varma R, Klein R, et al. Noncompliance with vision care guidelines in Latinos with type 2 diabetes mellitus: the Los Angeles Latino Eye Study. Ophthalmology 2006;113:1372-7.
67. Fong DS, Sharza M, Chen W, et al. Vision loss among diabetics in a group model Health Maintenance Organization (HMO). Am J Ophthalmol 2002;133:236-41.
68. Lee PP, Feldman ZW, Ostermann J, Brown DS. Longitudinal rates of annual eye examinations of persons with diabetes and chronic eye diseases. Ophthalmology 2003;110:1952-9.
69. The prevalence of retinopathy in impaired glucose tolerance and recent-onset diabetes in the Diabetes Prevention Program. Diabet Med 2007;24:137-44.
70. Klein BE, Moss SE, Klein R. Effect of pregnancy on progression of diabetic retinopathy. Diabetes Care 1990;13:34-40.
71. Chew EY, Mills JL, Metzger BE, et al. Metabolic control and progression of retinopathy. The Diabetes in Early Pregnancy Study. National Institute of Child Health and Human Development Diabetes in Early Pregnancy Study. Diabetes Care 1995;18:631-7.
72. Diabetes Control and Complications Trial Research Group. Effect of pregnancy on microvascular complications in the diabetes control and complications trial. Diabetes Care 2000;23:1084-91.
73. Williams GA, Scott IU, Haller JA, et al. Single-field fundus photography for diabetic retinopathy screening: a report by the American Academy of Ophthalmology. Ophthalmology 2004;111:1055-62.
74. Lin DY, Blumenkranz MS, Brothers RJ, Grosvenor DM. The sensitivity and specificity of single-field nonmydriatic monochromatic digital fundus photography with remote image interpretation for diabetic retinopathy screening: a comparison with ophthalmoscopy and standardized mydriatic color photography. Am J Ophthalmol 2002;134:204-13.
75. Larsen N, Godt J, Grunkin M, et al. Automated detection of diabetic retinopathy in a fundus photographic screening population. Invest Ophthalmol Vis Sci 2003;44:767-71.
76. Leese GP, Ellis JD, Morris AD, Ellingford A. Does direct ophthalmoscopy improve retinal screening for diabetic eye disease by retinal photography? Diabet Med 2002;19:867-9.
77. Ahmed J, Ward TP, Bursell SE, et al. The sensitivity and specificity of nonmydriatic digital stereoscopic retinal imaging in detecting diabetic retinopathy. Diabetes Care 2006;29:2205-9.
78. Rudnisky CJ, Hinz BJ, Tennant MT, et al. High-resolution stereoscopic digital fundus photography versus contact lens biomicroscopy for the detection of clinically significant macular edema. Ophthalmology 2002;109:267-74.
79. Cavallerano JD, Aiello LP, Cavallerano AA, et al. Nonmydriatic digital imaging alternative for annual retinal examination in persons with previously documented no or mild diabetic retinopathy. Am J Ophthalmol 2005;140:667-73.
80. Fonda SJ, Bursell SE, Lewis DG, et al. The relationship of a diabetes telehealth eye care program to standard eye care and change in diabetes health outcomes. Telemed J E Health 2007;13:635-44.
81. Conlin PR, Fisch BM, Cavallerano AA, et al. Nonmydriatic teleretinal imaging improves adherence to annual eye examinations in patients with diabetes. J Rehabil Res Dev 2006;43:733-40.
82. Diamond JP, McKinnon M, Barry C, et al. Non-mydriatic fundus photography: a viable alternative to fundoscopy for identification of diabetic retinopathy in an Aboriginal population in rural Western Australia? Aust N Z J Ophthalmol 1998;26:109-15.
83. Klein R, Klein BE. Screening for diabetic retinopathy, revisited. Am J Ophthalmol 2002;134:261-3.
84. Maberley D, Walker H, Koushik A, Cruess A. Screening for diabetic retinopathy in James Bay, Ontario: a cost-effectiveness analysis. CMAJ 2003;168:160-4.
85. Farley TF, Mandava N, Prall FR, Carsky C. Accuracy of primary care clinicians in screening for diabetic retinopathy using single-image retinal photography. Ann Fam Med 2008;6:428-34.
86. Diabetes Control and Complications Trial/Epidemiology of Diabetes Interventions and Complications Research Group. Prolonged effect of intensive therapy on the risk of retinopathy complications in patients with type 1 diabetes: 10 years after the Diabetes Control and Complications Trial. Arch Ophthalmol 2008;126:1707-15.

87. UK Prospective Diabetes Study (UKPDS). VIII. Study design, progress and performance. Diabetologia 1991;34:877-90.
88. Chew EY, Klein ML, Murphy RP, et al. Effects of aspirin on vitreous/preretinal hemorrhage in patients with diabetes mellitus. Early Treatment Diabetic Retinopathy Study report number 20. Arch Ophthalmol 1995;113:52-5.
89. Lueder GT, Silverstein J. Screening for retinopathy in the pediatric patient with type 1 diabetes mellitus. Pediatrics 2005;116:270-3.
90. American Academy of Pediatrics, American Association for Pediatric Ophthalmology and Strabismus, American Academy of Ophthalmology. Information Statement. Screening for Retinopathy in the Pediatric Patient with Type 1 Diabetes Mellitus. San Francisco, CA: American Academy of Ophthalmology; 2005. Available at: http://one.aao.org/CE/PracticeGuidelines/ClinicalStatements.aspx.
91. American Academy of Ophthalmology Preferred Practice Patterns Committee. Preferred Practice Pattern® Guidelines. Comprehensive Adult Medical Eye Evaluation. San Francisco, CA: American Academy of Ophthalmology; 2010. Available at: www.aao.org/ppp.
92. Klein R, Klein BE, Moss SE, et al. Glycosylated hemoglobin predicts the incidence and progression of diabetic retinopathy. JAMA 1988;260:2864-71.
93. Chew EY, Klein ML, Ferris FL, III, et al. Association of elevated serum lipid levels with retinal hard exudate in diabetic retinopathy. Early Treatment Diabetic Retinopathy Study (ETDRS) report 22. Arch Ophthalmol 1996;114:1079-84.
94. Klein R, Klein BE, Neider MW, et al. Diabetic retinopathy as detected using ophthalmoscopy, a nonmydriatic camera and a standard fundus camera. Ophthalmology 1985;92:485-91.
95. Klein R, Klein BE, Moss SE, et al. Retinopathy in young-onset diabetic patients. Diabetes Care 1985;8:311-5.
96. Frank RN, Hoffman WH, Podgor MJ, et al. Retinopathy in juvenile-onset diabetes of short duration. Ophthalmology 1980;87:1-9.
97. Palmberg P, Smith M, Waltman S, et al. The natural history of retinopathy in insulin-dependent juvenile-onset diabetes. Ophthalmology 1981;88:613-8.
98. Krolewski AS, Warram JH, Rand LI, et al. Risk of proliferative diabetic retinopathy in juvenile-onset type I diabetes: a 40-yr follow-up study. Diabetes Care 1986;9:443-52.
99. Klein R, Klein BE, Moss SE. Epidemiology of proliferative diabetic retinopathy. Diabetes Care 1992;15:1875-91.
100. Kaiser PK, Riemann CD, Sears JE, Lewis H. Macular traction detachment and diabetic macular edema associated with posterior hyaloidal traction. Am J Ophthalmol 2001;131:44-9.
101. Martidis A, Duker JS, Greenberg PB, et al. Intravitreal triamcinolone for refractory diabetic macular edema. Ophthalmology 2002;109:920-7.
102. Strom C, Sander B, Larsen N, et al. Diabetic macular edema assessed with optical coherence tomography and stereo fundus photography. Invest Ophthalmol Vis Sci 2002;43:241-5.
103. McDonald HR, Williams GA, Scott IU, et al. Laser scanning imaging for macular disease: a report by the American Academy of Ophthalmology. Ophthalmology 2007;114:1221-8.
104. Virgili G, Menchini F, Dimastrogiovanni AF, et al. Optical coherence tomography versus stereoscopic fundus photography or biomicroscopy for diagnosing diabetic macular edema: a systematic review. Invest Ophthalmol Vis Sci 2007;48:4963-73.
105. Browning DJ, Glassman AR, Aiello LP, et al. Relationship between optical coherence tomography-measured central retinal thickness and visual acuity in diabetic macular edema. Ophthalmology 2007;114:525-36.
106. Yannuzzi LA, Rohrer KT, Tindel LJ, et al. Fluorescein angiography complication survey. Ophthalmology 1986;93:611-7.
107. Sunness JS. The pregnant woman's eye. Surv Ophthalmol 1988;32:219-38.
108. Murphy RP, Egbert PR. Regression of iris neovascularization following panretinal photocoagulation. Arch Ophthalmol 1979;97:700-2.
109. Okamoto F, Okamoto Y, Fukuda S, et al. Vision-related quality of life and visual function following vitrectomy for proliferative diabetic retinopathy. Am J Ophthalmol 2008;145:1031-6.

110. Wittpenn JR, Rapoza P, Sternberg P, Jr., et al. Respiratory arrest following retrobulbar anesthesia. Ophthalmology 1986;93:867-70.
111. Early Treatment Diabetic Retinopathy Study Research Group. Photocoagulation for diabetic macular edema: Early Treatment Diabetic Retinopathy Study report number 4. Int Ophthalmol Clin 1987;27:265-72.
112. Elman MJ, Bressler NM, Qin H, et al. Expanded 2-year follow-up of ranibizumab plus prompt or deferred laser or triamcinolone plus prompt laser for diabetic macular edema. Ophthalmology 2011;118:609-14.
113. Ferris F. Early photocoagulation in patients with either type I or type II diabetes. Trans Am Ophthalmol Soc 1996;94:505-37.
114. Schatz H, Madeira D, McDonald HR, Johnson RN. Progressive enlargement of laser scars following grid laser photocoagulation for diffuse diabetic macular edema. Arch Ophthalmol 1991;109:1549-51.
115. Braun CI, Benson WE, Remaley NA, et al. Accommodative amplitudes in the Early Treatment Diabetic Retinopathy Study. Retina 1995;15:275-81.
116. Novak MA, Rice TA, Michels RG, Auer C. Vitreous hemorrhage after vitrectomy for diabetic retinopathy. Ophthalmology 1984;91:1485-9.
117. Schachat AP, Oyakawa RT, Michels RG, Rice TA. Complications of vitreous surgery for diabetic retinopathy. II. Postoperative complications. Ophthalmology 1983;90:522-30.
118. Wand M, Madigan JC, Gaudio AR, Sorokanich S. Neovascular glaucoma following pars plana vitrectomy for complications of diabetic retinopathy. Ophthalmic Surg 1990;21:113-8.
119. Aaberg TM, Van Horn DL. Late complications of pars plana vitreous surgery. Ophthalmology 1978;85:126-40.
120. Chu KM, Chen TT, Lee PY. Clinical results of pars plana vitrectomy in posterior-segment disorders. Ann Ophthalmol 1985;17:686-93.
121. Chew EY, Benson WE, Remaley NA, et al. Results after lens extraction in patients with diabetic retinopathy: early treatment diabetic retinopathy study report number 25. Arch Ophthalmol 1999;117:1600-6.
122. Gillies MC, Sutter FK, Simpson JM, et al. Intravitreal triamcinolone for refractory diabetic macular edema: two-year results of a double-masked, placebo-controlled, randomized clinical trial. Ophthalmology 2006;113:1533-8.
123. Chieh JJ, Roth DB, Liu M, et al. Intravitreal triamcinolone acetonide for diabetic macular edema. Retina 2005;25:828-34.
124. U.S. Food and Drug Administration, Center for Drug Evaluation and Research. Lucentis (ranibizumab injection). BLA 25156. Available at: www.accessdata.fda.gov/drugsatfda_docs/label/2012/125156s0069s0076lbl.pdf. Accessed October 30, 2012.
125. Diabetic Retinopathy Clinical Research N, Googe J, Brucker AJ, et al. Randomized trial evaluating short-term effects of intravitreal ranibizumab or triamcinolone acetonide on macular edema after focal/grid laser for diabetic macular edema in eyes also receiving panretinal photocoagulation. Retina 2011;31:1009-27.
126. Elman MJ, Aiello LP, Beck RW, et al. Diabetic Retinopathy Clinical Research Network. Randomized trial evaluating ranibizumab plus prompt or deferred laser or triamcinolone plus prompt laser for diabetic macular edema. Ophthalmology 2010;117:1064-77.
127. Ho AC, Scott IU, Kim SJ, et al. Anti-vascular endothelial growth factor pharmacotherapy for diabetic macular edema: a report by the American Academy of Ophthalmology. Ophthalmology 2012;119:2179-88.
128. Mitchell P, Bandello F, Schmidt-Erfurth U, et al. The RESTORE study: ranibizumab monotherapy or combined with laser versus laser monotherapy for diabetic macular edema. Ophthalmology 2011;118:615-25.
129. Nguyen QD, Brown DM, Marcus DM, et al. Ranibizumab for diabetic macular edema: results from 2 phase III randomized trials: RISE and RIDE. Ophthalmology 2012;119:789-801.
130. Guyer DR, D'Amico DJ, Smith CW. Subretinal fibrosis after laser photocoagulation for diabetic macular edema. Am J Ophthalmol 1992;113:652-6.

131. Han DP, Mieler WF, Burton TC. Submacular fibrosis after photocoagulation for diabetic macular edema. Am J Ophthalmol 1992;113:513-21.
132. Fong DS, Segal PP, Myers F, et al. Early Treatment Diabetic Retinopathy Study Research Group. Subretinal fibrosis in diabetic macular edema. ETDRS report 23. Arch Ophthalmol 1997;115:873-7.
133. Lewis H, Schachat AP, Haimann MH, et al. Choroidal neovascularization after laser photocoagulation for diabetic macular edema. Ophthalmology 1990;97:503-10; discussion 510-1.
134. Colucciello M. Vision loss due to macular edema induced by rosiglitazone treatment of diabetes mellitus. Arch Ophthalmol 2005;123:1273-5.
135. Ryan EH, Jr., Han DP, Ramsay RC, et al. Diabetic macular edema associated with glitazone use. Retina 2006;26:562-70.
136. Massin P, Duguid G, Erginay A, et al. Optical coherence tomography for evaluating diabetic macular edema before and after vitrectomy. Am J Ophthalmol 2003;135:169-77.
137. Otani T, Kishi S. A controlled study of vitrectomy for diabetic macular edema. Am J Ophthalmol 2002;134:214-9.
138. Yamamoto T, Hitani K, Tsukahara I, et al. Early postoperative retinal thickness changes and complications after vitrectomy for diabetic macular edema. Am J Ophthalmol 2003;135:14-9.
139. Diabetic Retinopathy Clinical Research Network. A randomized trial comparing intravitreal triamcinolone acetonide and focal/grid photocoagulation for diabetic macular edema. Ophthalmology 2008;115:1447-59.
140. Chew E, Strauber S, Beck R, et al. Diabetic Retinopathy Clinical Research Network. Randomized trial of peribulbar triamcinolone acetonide with and without focal photocoagulation for mild diabetic macular edema: a pilot study. Ophthalmology 2007;114:1190-6.
141. Jacobson DR, Murphy RP, Rosenthal AR. The treatment of angle neovascularization with panretinal photocoagulation. Ophthalmology 1979;86:1270-7.
142. Centers for Medicare and Medicaid Services. Physician Quality Reporting System. Available at: www.cms.gov/PQRS or www.aao.org/advocacy/reimbursement/pqri/reporting_options.cfm#5 (login required). Accessed October 26, 2012.
143. American Academy of Ophthalmology. Clinical Statement. Eye MD Examination Report. San Francisco, CA: American Academy of Ophthalmology; 2005. Available at: http://one.aao.org/CE/PracticeGuidelines/ClinicalStatements.aspx.
144. American Academy of Ophthalmology Vision Rehabilitation Committee. Preferred Practice Pattern® Guidelines. Vision Rehabilitation for Adults. San Francisco, CA: American Academy of Ophthalmology; 2012. Available at: www.aao.org/ppp.
145. Stelmack JA, Tang XC, Reda DJ, et al, LOVIT Study Group. Outcomes of the Veterans Affairs Low Vision Intervention Trial (LOVIT). Arch Ophthalmol 2008;126:608-17.
146. Ho T, Smiddy WE, Flynn HW Jr. Vitrectomy in the management of diabetic eye disease. Surv Ophthalmol 1992;37:190-202.
147. Klein R. Hyperglycemia and microvascular and macrovascular disease in diabetes. Diabetes Care 1995;18:258-68.
148. Early worsening of diabetic retinopathy in the Diabetes Control and Complications Trial. Arch Ophthalmol 1998;116:874-86.
149. Weinstein MC, Stason WB. Foundations of cost-effectiveness analysis for health and medical practices. N Engl J Med 1977;296:716-21.
150. Brown GC, Brown MM, Sharma S, et al. Value-based medicine and ophthalmology: an appraisal of cost-utility analyses. Trans Am Ophthalmol Soc 2004;102:177-85; discussion 185-8.
151. Torgerson DJ, Raftery J. Economic notes. Discounting. BMJ 1999;319:914-5.
152. Siegel JE, Torrance GW, Russell LB, et al. Guidelines for pharmacoeconomic studies. Recommendations from the panel on cost effectiveness in health and medicine. Panel on cost Effectiveness in Health and Medicine. Pharmacoeconomics 1997;11:159-68.
153. Brown MM, Brown GC, Sharma S. Value-based medicine. Evidence-Based Ophthalmology 2006;7:93-100.
154. Javitt JC, Canner JK, Sommer A. Cost effectiveness of current approaches to the control of retinopathy in type I diabetics. Ophthalmology 1989;96:255-64.

155. Dasbach EJ, Fryback DG, Newcomb PA, et al. Cost-effectiveness of strategies for detecting diabetic retinopathy. Med Care 1991;29:20-39.
156. Javitt JC, Aiello LP, Bassi LJ, et al. Detecting and treating retinopathy in patients with type I diabetes mellitus. Savings associated with improved implementation of current guidelines. American Academy of Ophthalmology. Ophthalmology 1991;98:1565-73; discussion 1574.
157. Javitt JC, Aiello LP. Cost-effectiveness of detecting and treating diabetic retinopathy. Ann Intern Med 1996;124:164-9.
158. Sharma S, Brown GC, Brown MM, et al. The cost-effectiveness of grid laser photocoagulation for the treatment of diabetic macular edema: results of a patient-based cost-utility analysis. Curr Opin Ophthalmol 2000;11:175-9.
159. Busbee BG, Brown MM, Brown GC, Sharma S. CME review: A cost-utility analysis of laser photocoagulation for extrafoveal choroidal neovascularization. Retina 2003;23:279-87; quiz 443-4.
160. Gray A, Raikou M, McGuire A, et al. United Kingdom Prospective Diabetes Study Group. Cost effectiveness of an intensive blood glucose control policy in patients with type 2 diabetes: economic analysis alongside randomised controlled trial (UKPDS 41). BMJ 2000;320:1373-8.
161. Crijns H, Casparie AF, Hendrikse F. Continuous computer simulation analysis of the cost-effectiveness of screening and treating diabetic retinopathy. Int J Technol Assess Health Care 1999;15:198-206.

AMERICAN ACADEMY OF OPHTHALMOLOGY
The Eye M.D. Association

P.O. Box 7424
San Francisco,
California 94120-7424
415.561.8500

Diabetic Retinopathy
2008 (4th Printing 2012)